

Case discussion

Bony injuries in upper extremity

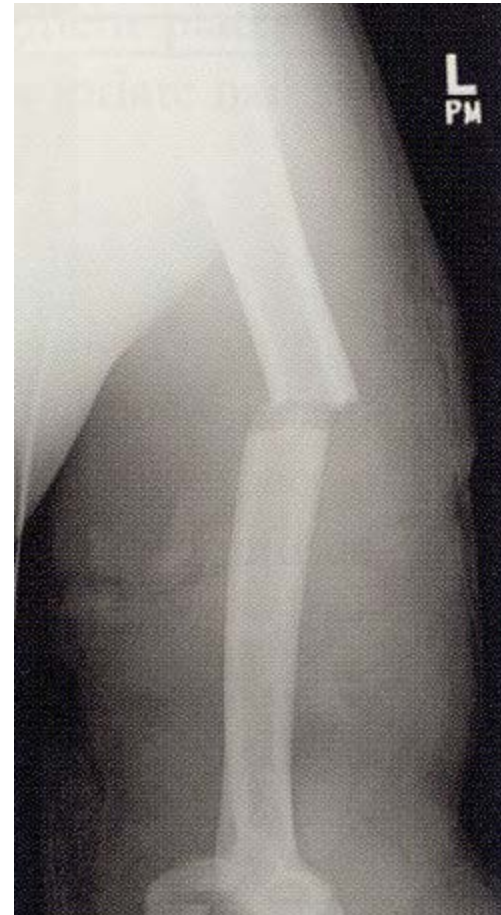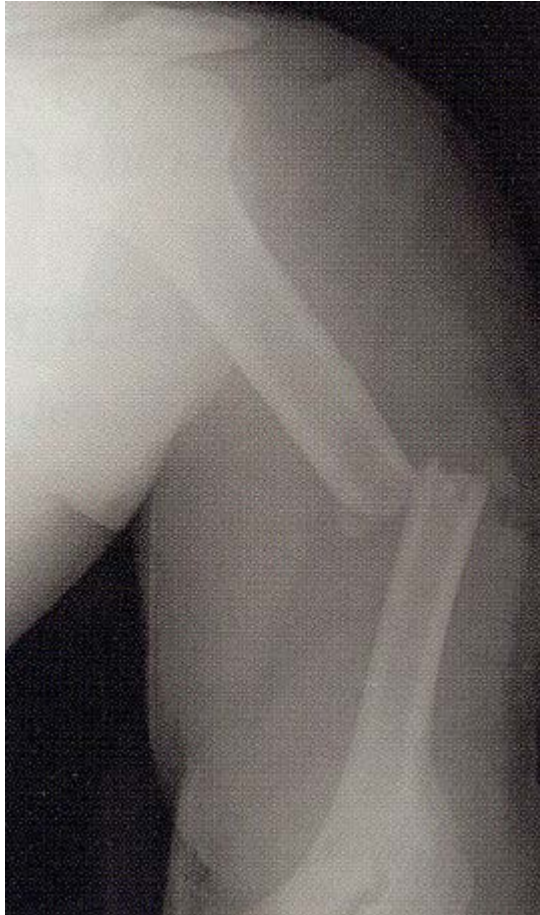Scope of discussion

- The clinical diagnosis
- Important other history and physical examination
- plan of other investigation (if need)
- X-ray appearance
- Recommended management (step by step)
- Early complication anticipated and prevention

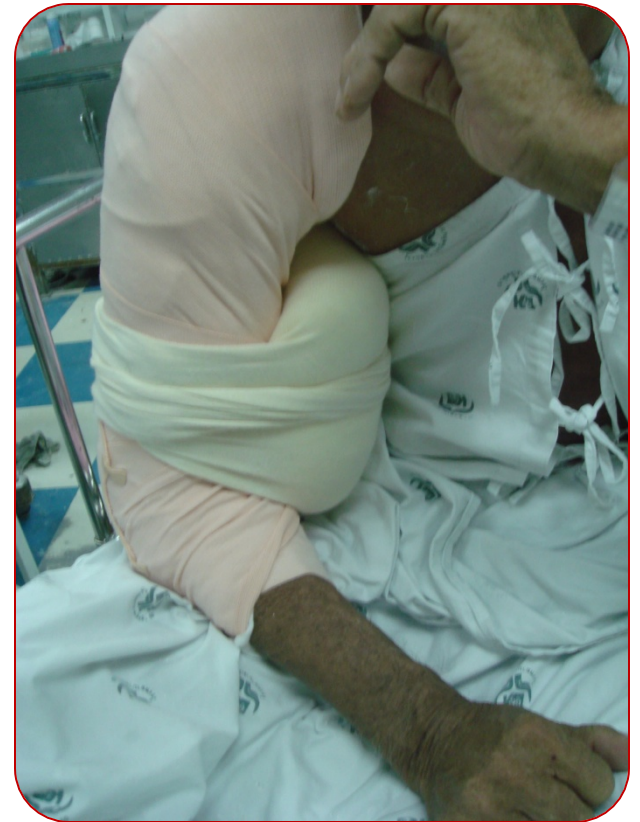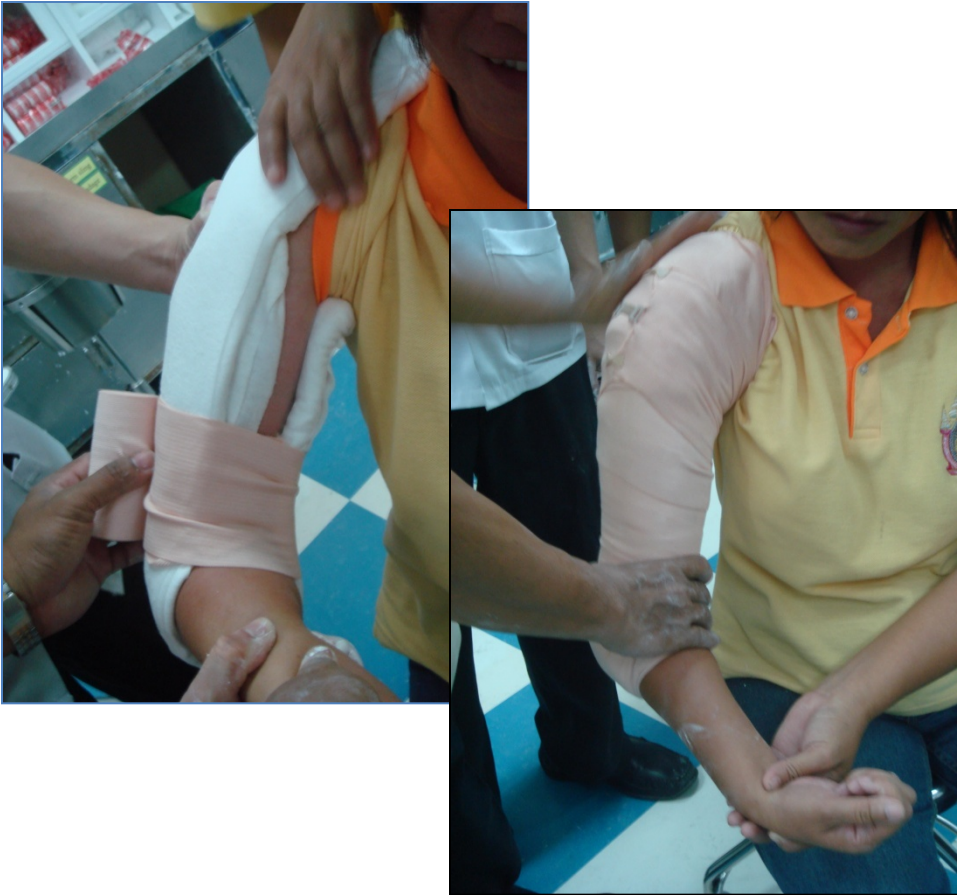Case 1

- A 18-year-old woman had motorcycle accident. She was conscious and alert.
- Physical examination revealed contusion with deformity at mid-upper arm.
- Peripheral pulse was intact.
- No other injuries were identified.

Radiography



U-Slap (Coaptation splint, Sugar tong)

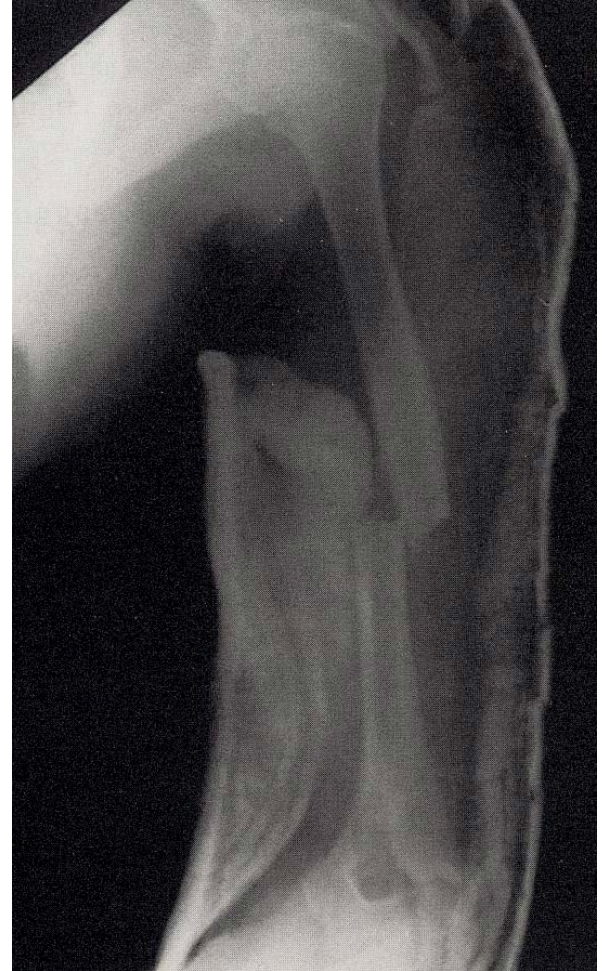


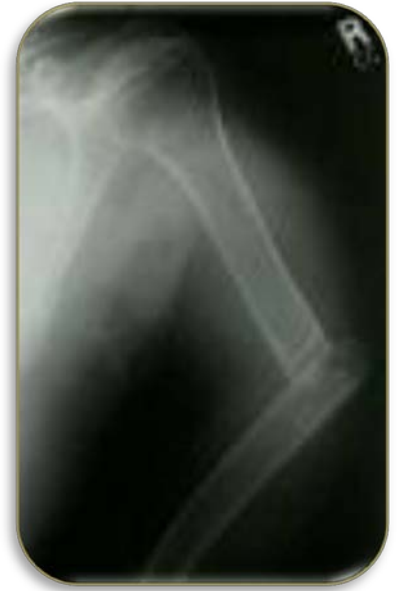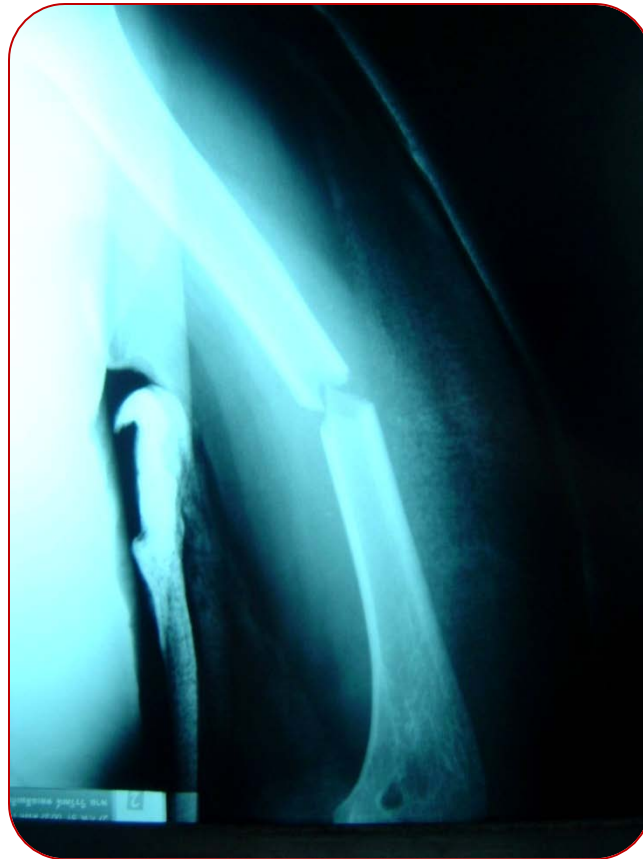
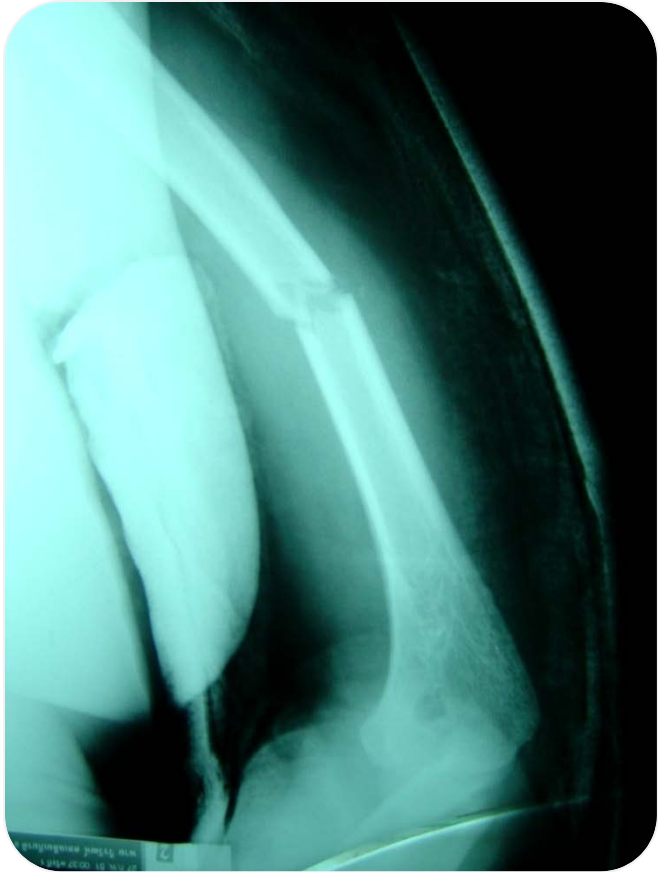Scope of discussion 1.2

Please describe

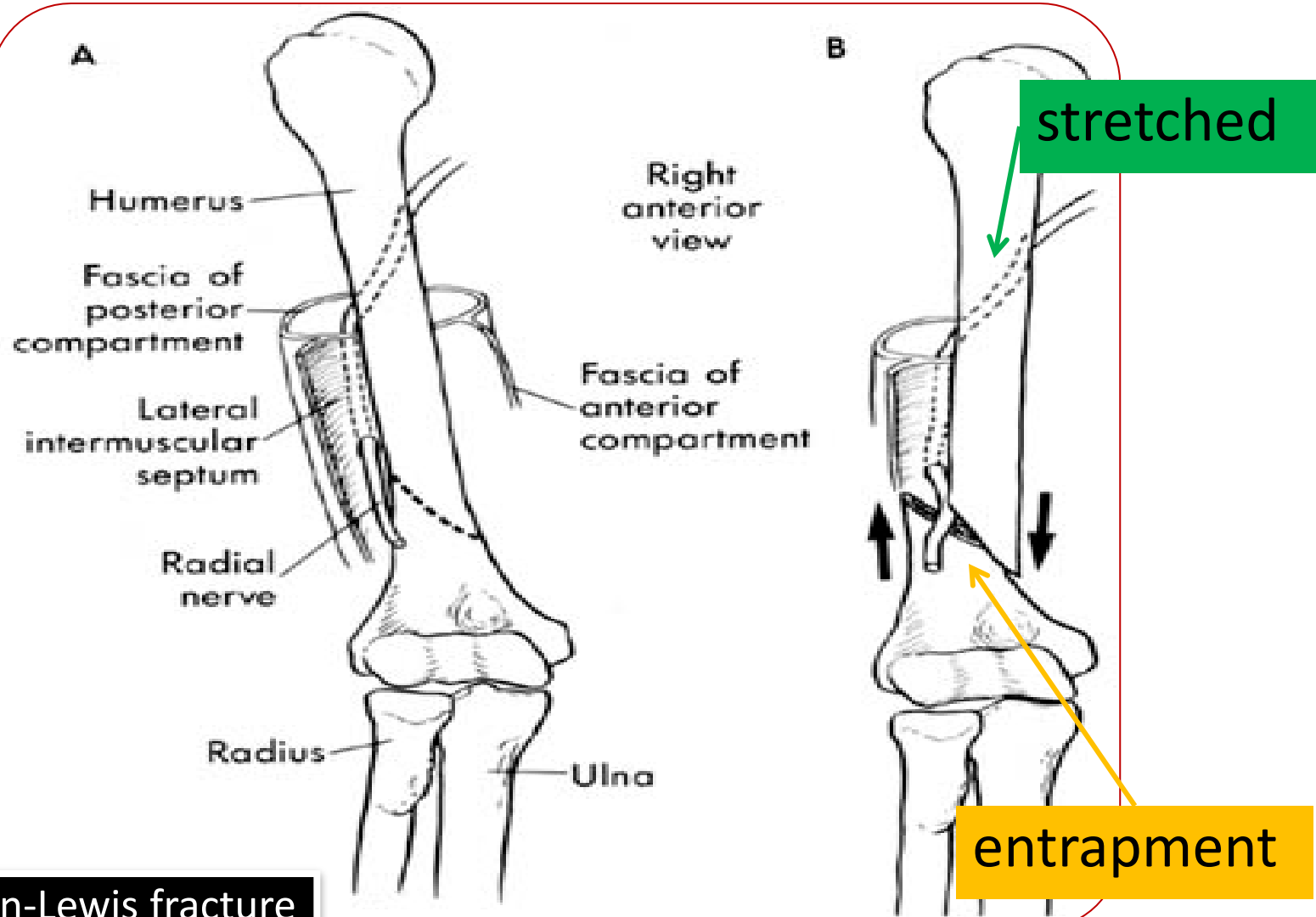
- Bony alignment after reduction
- The etiology, pathology and appropriated treatment in abnormal examination on this patient

Discussion 1.2





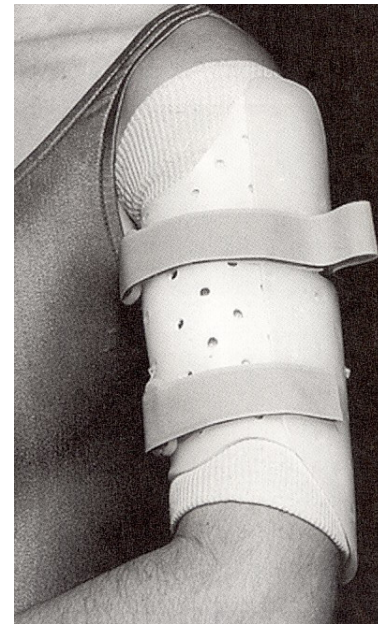
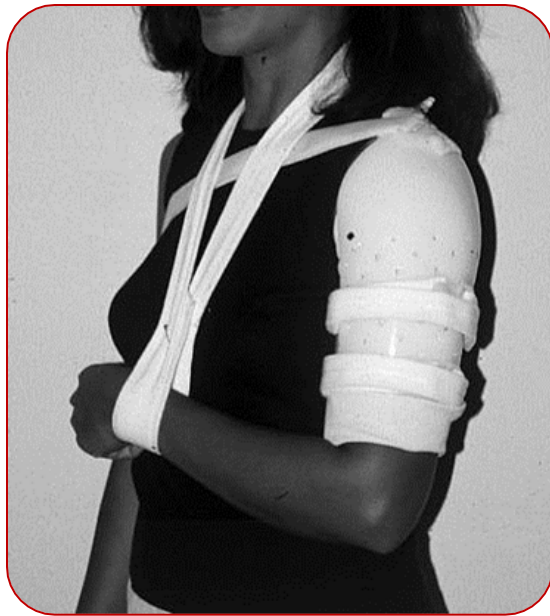a spiral fracture with radial nerve injury



Holstein-Lewis fracture

Functional brace

Use soft tissue compression to effect fracture reduction



Surgery

- Unacceptable fracture alignment
- Post-reduction or associated neurovascular injury
- Nonunion of fracture
- Open fracture
- Multiple trauma
- Floating elbow
- Pathologic fracture

