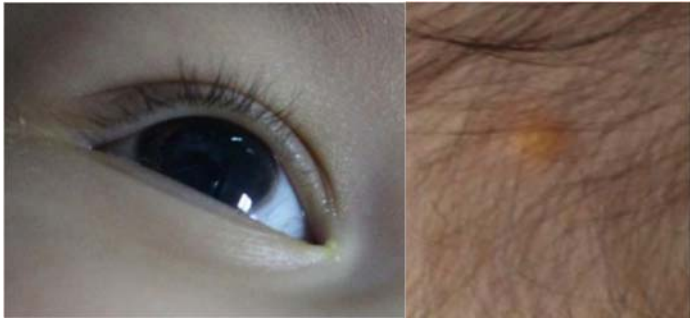

Case 8

An 8 month-old boy from Bangkok

Chief complaint: Two discrete yellowish papules on the scalp for 1 month



(Fig. 8.1)

Present illness:

One month PTA, the patient developed right eye redness which was treated with a topical antibiotic and resolved in few days.

Two months PTA, the patient's mother noticed three discrete yellowish papules on his scalp, not tender.

Two weeks PTA, he developed blurred edges at corneoscleral limbus of the right eye as shown in the photograph.

Past history:

No underlying diseases

Normal development, complete vaccination

Physical examination:

HEENT: No pale conjunctivae, anicteric sclerae

Slit-lamp examination: A yellowish mass close to inferior periphery of the iris without corneal involvement

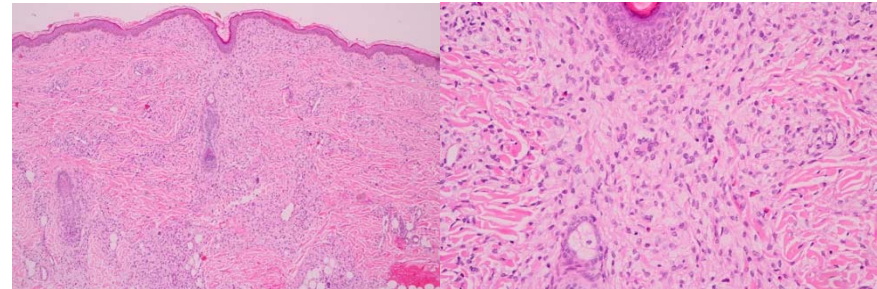
Lymph node: Not palpable

Extremities: No hepatosplenomegaly

Dermatological examination: (Fig. 8.1)

- Three discrete orange-yellowish dome-shaped papules, 3 mm in size on the scalp.
- No similar cutaneous lesions were present on the neck, trunk, or extremities

Histopathology: (S17-20287, Scalp) (Fig. 8.2)



(Fig. 8.2)

- Dense dermal infiltrate of histiocytes, foamy histiocytes intermingled with few lymphocytes and eosinophils
- A few Touton giant cells are presented

Laboratory investigations:

- CBC: Hct 38.8 %, WBC 9,100 cells/ μ L (N 12, L 79%, Mono 2%, Eo 6%), Platelet 408,000 cells/ μ L
- Chest X-ray: No active disease

Diagnosis: Juvenile xanthogranuloma with iris involvement

Treatment: Prednisolone acetate ophthalmic suspension 1% 1 drop four times a day with slow taper

Presenter: Noppanun Chalermroj, MD

Consultant: Pamela Chayavichitsilp, MD

Discussion:

Juvenile xanthogranuloma (JXG) is a benign histiocytic proliferation typically seen in infants and children.¹ The disorder was initially described by Adamson in 1905. JXG belongs to non-Langerhans cell (class II) histiocytoses (non-LCHs), which are characterized by the proliferation of macrophages together with multinucleated foreign-body type giant cells. The most commonly observed non-LCH lesion is due to tissue response to a foreign body.²

JXG usually presents at birth and is characterized by the development of solitary or multiple papules or nodules, which may be yellow, pink, or brown in color. It may present as a solitary lesion or multiple in number and most commonly involves the skin of the head, neck, and extremities. Lesions vary in size from 5 to 20 mm. Visceral involvement is rare, but there is a predilection for the lungs, spleen, testis, pericardium, and gastrointestinal tract. The most frequent site for extracutaneous involvement is the uveal tract, in which JXG is typically seen as a yellowish iridic mass.³ Ocular involvement may occur without concomitant skin involvement.

Ocular manifestations of JXG have been reported in approximately 10 % of affected individuals. Ocular JXG mainly involves the iris, and can present with spontaneous hyphema; JXG is the most common cause of hyphema in children. Infiltration of the anterior chamber angle and trabecular meshwork can lead to

secondary unilateral glaucoma and potentially to blindness. Presentation with uveitis has also been reported. In contrast to cutaneous JXG, which is self-limiting, ocular JXG is more persistent and sight-threatening, and thus often requires treatment^{4,5}

In adults, JXG may occur in all ages, but is infrequent and tends to be more severe. The male to female ratio of cutaneous JXG is about 1.4:1 in children, while in adults no sex predilection exists.⁶

The etiology is unknown, even though it is believed to result from confirmation of clinical diagnosis can be made by skin biopsy. Differential diagnoses of limbal lesions include dermoid, lipodermoid, pterygium, pyogenic granuloma, foreign body granuloma, nodular fasciitis, primary xanthoma, histiocytoma, lymphoproliferative lesions, and neoplasia.^{1,5,7,8}

Histologically, JXG consists of a well demarcated mixed infiltrates of mononuclear histiocytes with eosinophilic vacuolated cytoplasm and multinucleated giant cells (so-called Touton giant cells) on a background of scattered lymphocytes, eosinophils, neutrophils and mast cells. Immunostaining can confirm the diagnosis of JXG with positivity for CD68 and CD163 in histiocytes. Stains for protein S-100P and CD1a are negative, differentiating it from LCH.⁵

JXG is usually a self-limiting disorder and has a good prognosis with most lesions resolving within 1 to 5 years,⁹ especially in cases of cutaneous lesions. Unlike the cutaneous form, systemic JXG has been reported to possibly cause significant complications requiring aggressive medical care.¹⁰

For ocular JXG, currently there is no standard of care. Surgical resection of local, non-infiltrating uveal lesions, by iridectomy or iridocyclectomy, has been reported. However, nonsurgical approaches are preferred because they pose a lower risk of intraocular bleeding. Initial medical management often consists of

topical or local corticosteroid therapy, which can be successful. Localized radiotherapy has been associated with a risk of cataract formation.¹¹

Therefore ophthalmologic screening of patients with JXG should be particularly considered in patients with risk factors such as multiple skin lesions, new diagnosis, and age of 2 years or younger.¹²

References:

1. Mocan MC, Bozkurt B, Orhan D, et al. Juvenile xanthogranuloma of the corneal limbus: report of two cases and review of the literature. *Cornea* 2008;27:739-42.
2. Kraus MD, Haley JC, Ruiz R, et al. "Juvenile" xanthogranuloma: an immunophenotypic study with a reappraisal of histogenesis. *Am J Dermatopathol* 2001;23:104-11.
3. Rad AS, Kheradvar A. Juvenile xanthogranuloma: concurrent involvement of skin and eye. *Cornea*. 2001 Oct;20(7):760-2.
4. Weitzman S, Jaffe R. Uncommon histiocytic disorders: The non-Langerhans cell histiocytoses. *Pediatr Blood Cancer* 2005;45:256-64.
5. Kontos G, Borooh S, Khan A, Fleck BW, Coupland SE. The epidemiology, clinical characteristics, histopathology and management of juvenile- and adult-onset corneoscleral limbus xanthogranuloma. *Graefes Arch Clin Exp Ophthalmol* 2016;254:413-20.
6. Pajaziti L, Hapçiu SR, Pajaziti A. Juvenile xanthogranuloma: a case report and review of the literature. *BMC Res Notes* 2014;7:174.
7. Dehner LP: Juvenile xanthogranuloma in the first decades of life. A clinicopathologic study of 174 cases with cutaneous and extracutaneous manifestations. *Am J Surg Pathol* 2003, 5:579-93
8. De Keyser C, Maudgal P, Legius E, Van Ginderdeuren R, Casteels I. Juvenile xanthogranuloma of the corneoscleral limbus: report of two cases. *Ophthalmic Genet* 2011;32:54-6.
9. Chaudhry IA, Al-Jishi Z, Shamsi FA, Riley F. Juvenile xanthogranuloma of the corneoscleral limbus: case report and review of the literature. *Surv Ophthalmol* 2004;49:608-14.
10. Niu L, Zhang C, Meng F, Cai R, Bi Y, Wang Y, Xu J. Ocular juvenile xanthogranuloma. *Optom Vis Sci* 2015;92:e126-33.
11. Ashkenazy N, Henry CR, Abbey AM, McKeown CA, Berrocal AM, Murray TG. Successful treatment of juvenile xanthogranuloma using bevacizumab. *J AAPOS* 2014;18:295-7.
12. Chang MW, Frieden IJ, Good W. The risk intraocular juvenile xanthogranuloma: survey of current practices and assessment of risk. *J Am Acad Dermatol* 1996;34:445-9.