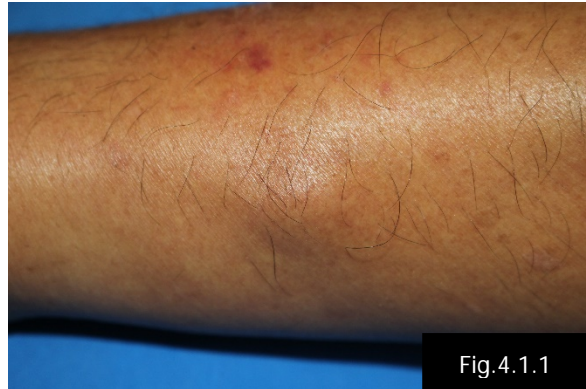


#### Case 4.1

A 68-year-old Thai man from Phetchaburi

**Chief complaint:** Solitary asymptomatic nodule on left forearm for 1 year



#### Present illness:

One year earlier, the patient noticed a small, skin-colored nodule on extensor side of his left forearm. Remarkably, it seemed increasing in size over the past 3 months. He had a history of gardening in spare time. He denied a history of trauma, arthropod bite or fever.

**Past history:** Well-controlled hypertension and dyslipidemia receiving aspirin 81 mg/day, enalapril 10 mg/day, and atorvastatin 40 mg/day

**Family history:** There was no family history of similar lesion.

**Physical examination:** Other systems revealed no abnormality.

#### Dermatological examination:

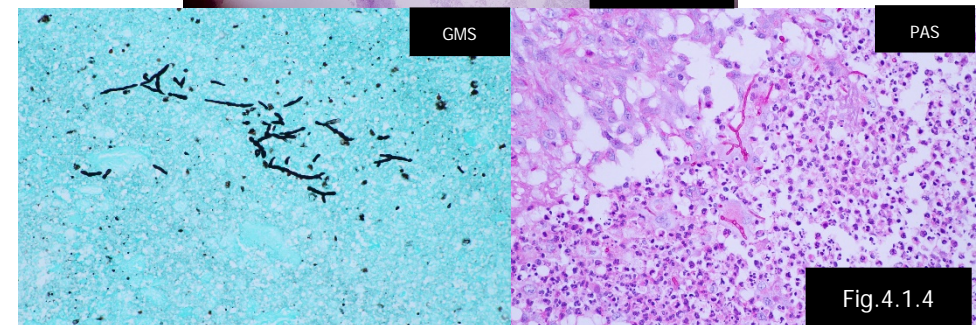
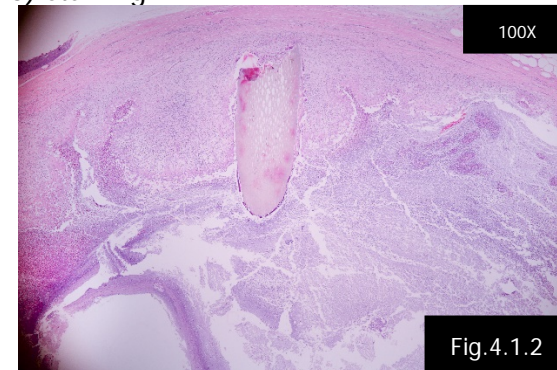
- Solitary, non-tender, firm, movable, skin-colored nodule with 1 cm in diameter on left forearm (Fig.4.1.1)

#### Histopathology (S19-018723, Left forearm):

- Large cystic cavity of suppuration, and surrounded by cellular infiltrate of granulomatous inflammation
- Fibrous capsule around inflammatory component
- Pigmented hyphae and foreign body material is noted (Fig.4.1.2)

#### Special stain:

- Pigmented hyphae highlighted by PAS (Fig.4.1.4) and GMS (Fig.4.1.3) staining



#### Laboratory investigations:

- CBC: Hb 12.4 g/dL, Hct 36.3%, Plt 273,000 /mm<sup>3</sup>, WBC 7,000 /mm<sup>3</sup> (N 70%, L 21%, M 7%, E 1%, B 1%)
- AST/ALT: 20/14 U/L
- BUN/Cr: 10/0.8 mg/dl

**Presenter:** Pitchaya Jaruvijitrattana, MD

**Consultant:** Poonkiat Suchonwanit, MD