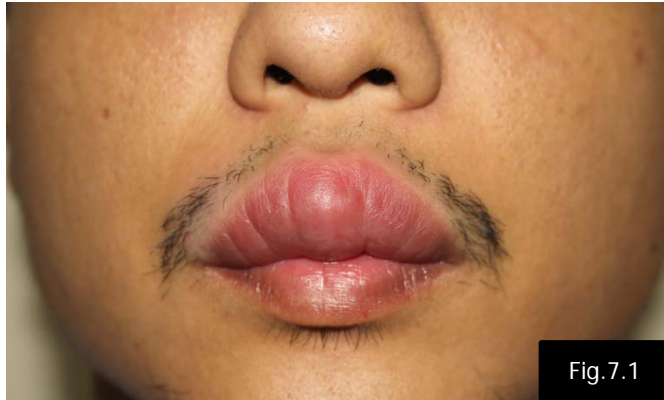

## Case 7

A 26-year-old Thai man from Saraburi

**Chief complaint:** Persistent upper lip swelling for 1 year



### Present illness:

He gradually developed diffuse painless upper lip swelling for one year. Initially, symptoms tend to wax and wane. He noted that the symptom was aggravated by smoking, drinking alcohol, and eating spicy food. The swelling persist during the past 3 months. He had no fever, facial swelling, facial palsy, intraoral lesion, or genital lesion. He also denied any GI symptoms or other organ-specific symptoms.

One month earlier, he was treated with oral prednisolone (15 mg/day) for 14 days without improvement.

### Past history:

- No underlying disease
- No history of drug/food allergy, angioedema or anaphylaxis
- No history of local injection, prior procedure or trauma on lips or face
- Occasional smoking and social alcohol drinking

**Family history:** There was no family history of a similar illness.

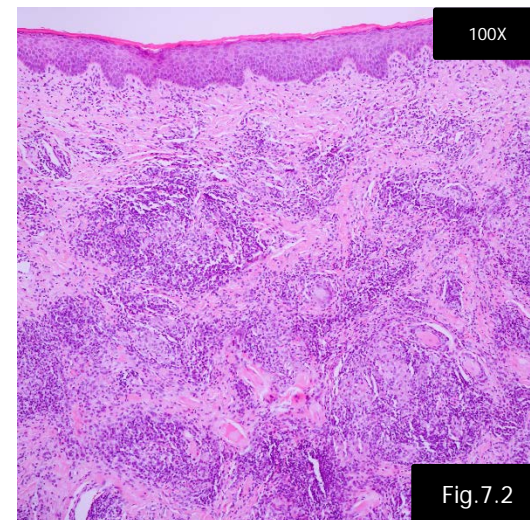
**Physical examination:** Unremarkable

### Dermatological examination:

- A localized upper lip swelling with firm consistency, reddish-pink color, and smooth surface
- No facial palsy, gingival swelling, ulcer, or fissured tongue (Fig.7.1)

### Histopathology (S19-009335, upper lip):

- Nodular cell infiltrates of lymphocytes, plasma cells, histiocytes and multinucleated giant cells forming small tuberculoid granuloma in the dermis (Fig.7.2)



**Laboratory investigations:**

- CBC: Hb 12.2 g/dL, Hct 35.9%, Plt 226,000 cells/mm<sup>3</sup>, WBC 7,180 cells/mm<sup>3</sup> (N 53%, L 41%, M 4%, E 2%)
- AST/ALT: 20/15 U/L, ALP/GGT: 83/24 U/L  
TP/Alb: 78.6/42.2 g/L, TB/DB: 0.8/0.3 mg/dL
- Anti-HCV: Negative
- HBsAg: Negative
- Stool examination: WBC negative, RBC negative, parasite not found
- Chest X-ray: Unremarkable

**Diagnosis:** Cheilitis granulomatosa

**Treatment:**

- Intralesional triamcinolone acetonide 10 mg/ml
- Methotrexate 10 mg per oral once per week
- Folic acid 5 mg per oral once daily

**Presenter:** Thanapon Sutharaphan, MD

**Consultant:** Asst. Prof. Vasanop Vachiramom, MD

**Discussion:**

Cheilitis granulomatosa (CG) is a rare inflammatory disease characterized by idiopathic recurrent or persistent painless swelling of one or both lips. CG is referred as to a subtype of orofacial granulomatosis (OFG). This clinical entity consisted of facial and oral swelling, which is non-necrotizing granulomatous inflammation in the absence of systemic diseases such as Crohn's disease and sarcoidosis.<sup>1</sup> When a triad of swelling of the lip, facial nerve paralysis, and fissured tongue is complete, it is so-called Melkersson–Rosenthal syndrome (MRS).<sup>1, 2</sup>

The etiology of CG has not been well established, however, several explanations have been proposed—including genetic predisposition and environmental exposures.<sup>1</sup> A report raised a

probable role of UVB- photosensitivity in pathogenesis.<sup>3</sup> Allergic reactions to food, food additives, cobalt, and dental materials are supposed to be causes of CG.<sup>1, 4</sup> However, some patients did not mention a possible relevant allergy.<sup>5</sup> Therefore, the role of patch testing in the diagnosis of CG remains unclear.<sup>1</sup> CG has been reported to precede full-blown intestinal manifestations of Crohn disease.<sup>6</sup> Some studies proposed that CG might represent extraintestinal Crohn disease.<sup>5</sup> However, it is controversy to perform routine screening gastrointestinal tract investigations, for instance, colonoscopy or gastroduodenoscopy, in patients with no history of gastrointestinal symptoms.<sup>5, 6</sup> Instead, long term follow up is of paramount importance. CG has been noted as a localized form of sarcoidosis. Focal nodular lesions are more suggestive sarcoidosis than diffuse lip swelling.<sup>5</sup>

The differential diagnosis includes other granulomatous diseases such as foreign body reaction, mycobacterial infection (tuberculosis, leprosy, atypical mycobacterium), deep fungal infection (histoplasmosis), sarcoidosis, Crohn's disease, Wegener's granulomatosis; other dermal diseases such as amyloidosis, minor salivary gland tumor, rosacea, pseudolymphoma; and angioedema that caused by medications (such as ACE inhibitors, calcium channel blockers), as well as, hereditary C1 esterase deficiency.

Histopathology of CG characterized by the presence of non-caseating granulomas and perivascular lymphocytic infiltration in the absence of other identifiable causes,<sup>5</sup> i.e., foreign body, sarcoidosis, or infection (tuberculosis, cutaneous leishmaniasis or leprosy). Histopathological findings are not pathognomonic and may be indistinguishable from Crohn's disease, sarcoidosis, or longstanding Wegener's granulomatosis.<sup>1, 5</sup> Therefore, the diagnosis of CG is made by correlation of the patient history, clinical features and supported by the histopathologic findings.<sup>2, 5</sup>

Spontaneous remission is unlikely to happen.<sup>1</sup> The literature offers only case reports and series. There is no gold standard treatment for CG due to the rarity of the disease. Treatment selection

are individually based on local settings and concurrent diseases. Intralesional triamcinolone is suggested by many authors as the first choice therapy in the acute stages of the disease according to satisfactory short-term results.<sup>2, 7</sup> Its dosage ranged from 10-40 mg/doses with weeks to months interval among each injection.<sup>8, 9</sup> Nevertheless, recurrences of lip swelling commonly occur. Nonsteroidal systemic modalities, such as methotrexate, clofazimine, hydroxychloroquine, sulfasalazine, thalidomide, fumaric acid esters, tranilast or systemic oral antibiotics (e.g., tetracycline, minocycline, doxycycline, roxithromycin, dapsone, and metronidazole) were also reported with moderate responses.<sup>7, 8</sup> Recent data revealed that anti-TNF antibodies (e.g., infliximab, adalimumab) led to successful results in cases with refractory to conventional therapies.<sup>7, 10</sup> Surgical intervention should be reserved for refractory and severely disfiguring lip. It showed the moderately effective outcome, however, minor recurrence of lip swelling may occur as well.<sup>2, 5</sup>

#### References:

1. Grave B, McCullough M, Wiesenfeld D. Orofacial granulomatosis--a 20-year review. *Oral Dis.* 2009;15:46-51.
2. Wehl G, Rauchenzauner M. A Systematic Review of the Literature of the Three Related Disease Entities Cheilitis Granulomatosa, Orofacial Granulomatosis and Melkersson - Rosenthal Syndrome. *Curr Pediatr Rev.* 2018;14:196-203.
3. Kuno Y, Sakakibara S, Mizuno N. Actinic cheilitis granulomatosa. *J Dermatol.* 1992;19:556-62.
4. Schlarbaum JP, Kimyon RS, Liou YL, Voller LM, Seyfer SJ, Warshaw EM. Hold the spice: Allergy to garlic and sulfites--Possible relevance in a patient with cheilitis granulomatosa. *Contact Dermatitis.* 2019.
5. Van der Waal RI, Schulten EA, van der Meij EH, van de Scheur MR, Starink TM, van der Waal I. Cheilitis granulomatosa: overview of 13 patients with long-term follow-up--results of management. *Int J Dermatol.* 2002;41:225-9.
6. Dupuy A, Cosnes J, Revuz J, Delchier JC, Gendre JP, Cosnes A. Oral Crohn disease: clinical characteristics and long-term follow-up of 9 cases. *Arch Dermatol.* 1999;135:439-42.
7. Banks T, Gada S. A comprehensive review of current treatments for granulomatous cheilitis. *Br J Dermatol.* 2012;166:934-7.
8. Critchlow WA, Chang D. Cheilitis granulomatosa: a review. *Head Neck Pathol.* 2014;8:209-13.
9. Brajac I. Familiar occurrence of multiple primary epidermoid cysts and trichostasis spinulosa: a novel skin phenotype associated with inherited sensorineural deafness. *J Eur Acad Dermatol Venereol.* 2010;24:362-3.
10. Jahnke I, Stieler K, Blumeyer A, Bartels NG, Blume-Peytavi U. Successful treatment of childhood cheilitis granulomatosa with infliximab. *J Dtsch Dermatol Ges.* 2017;15:1241-3.