



# Interhospital Conference

## Case 1

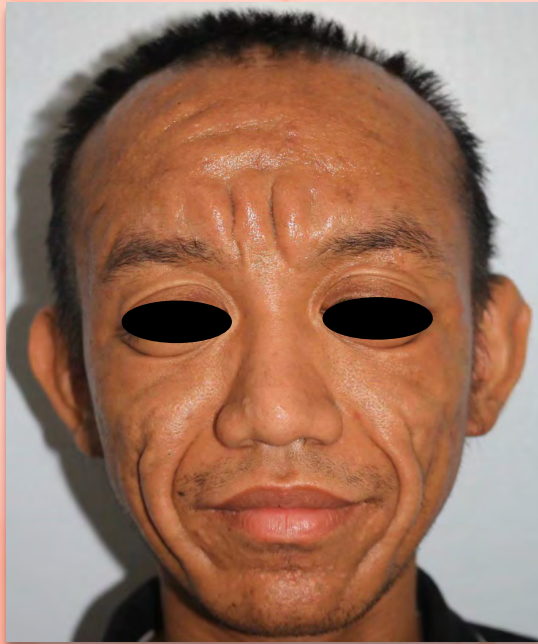**Korn Triyangkulsri, MD**

**Kumutnart Chanprapaph, MD**

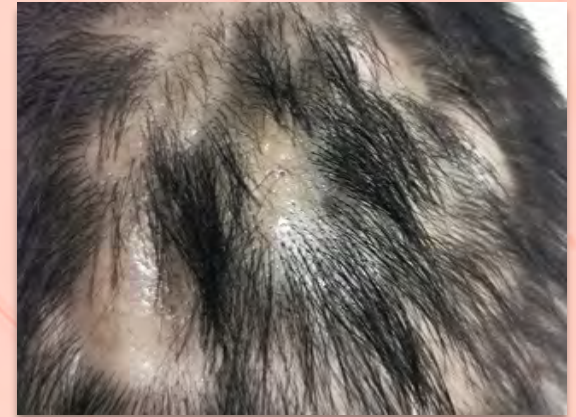

# A 24-year-old male

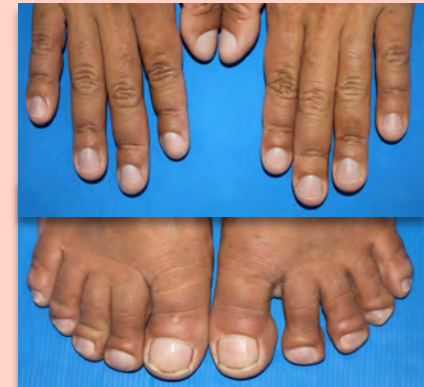Progressive thickening and furrowing of skin for 7 years



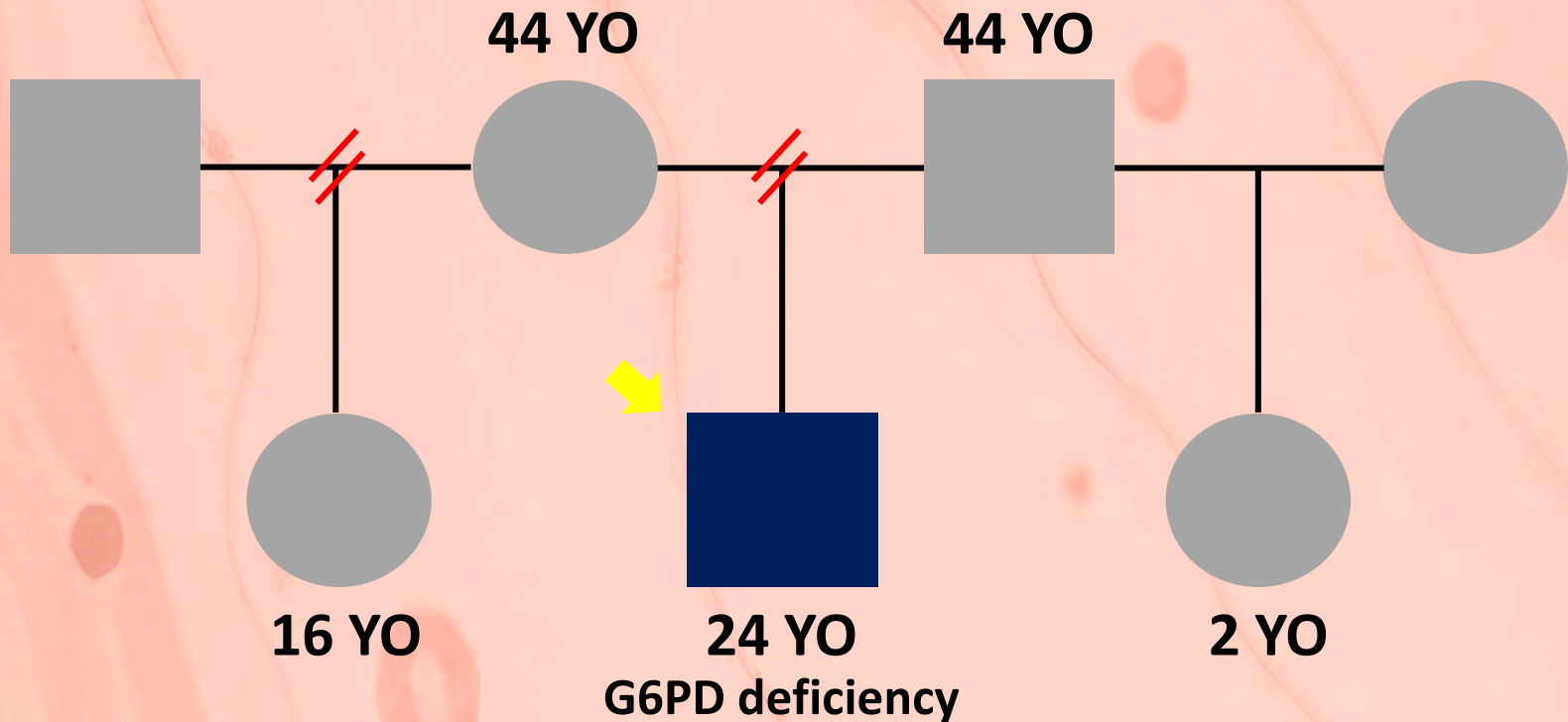
Hyperhidrosis of scalp



Clubbing fingers



# Pedigree



No history of consanguinity

None of his family members share same symptoms

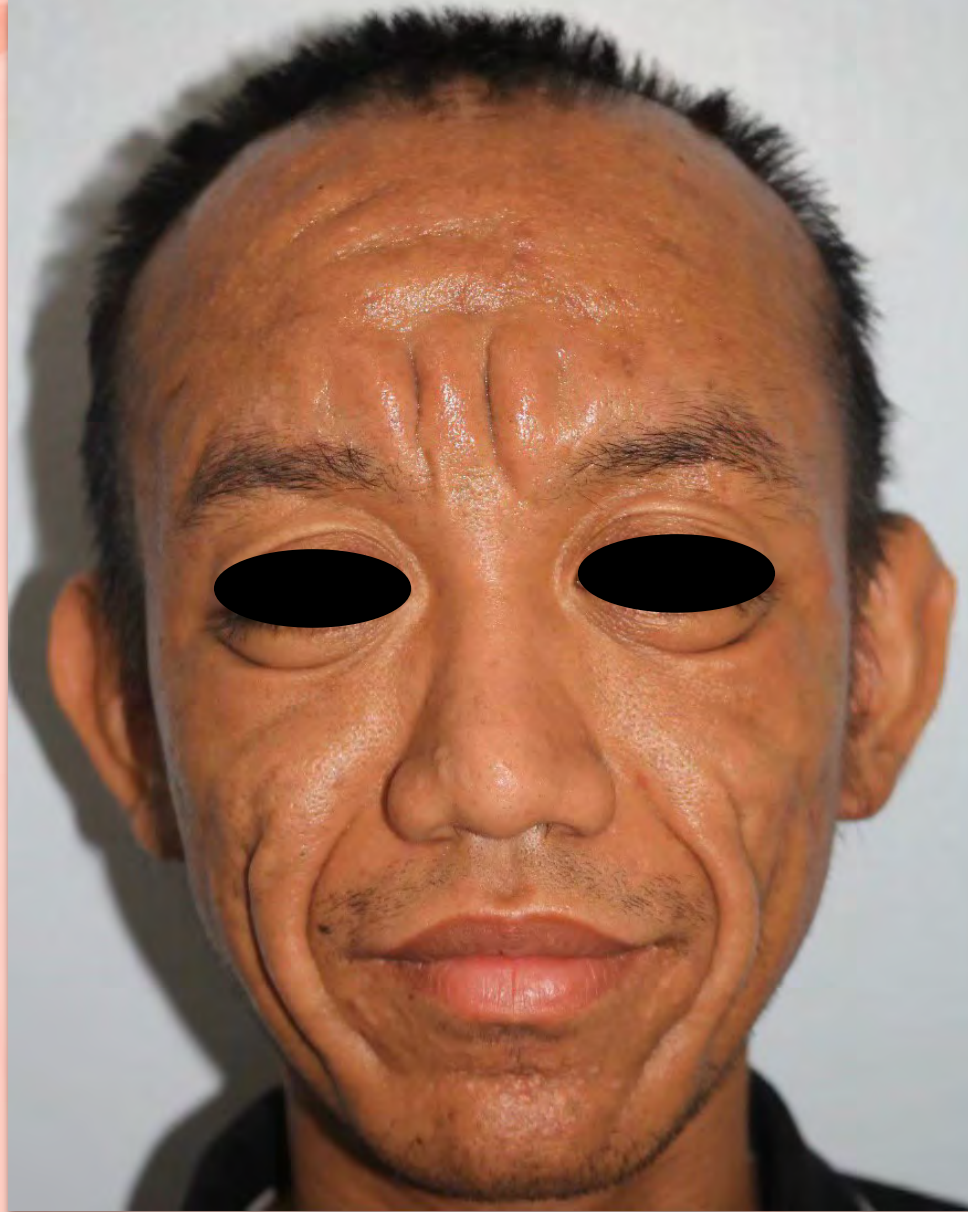# Physical examination



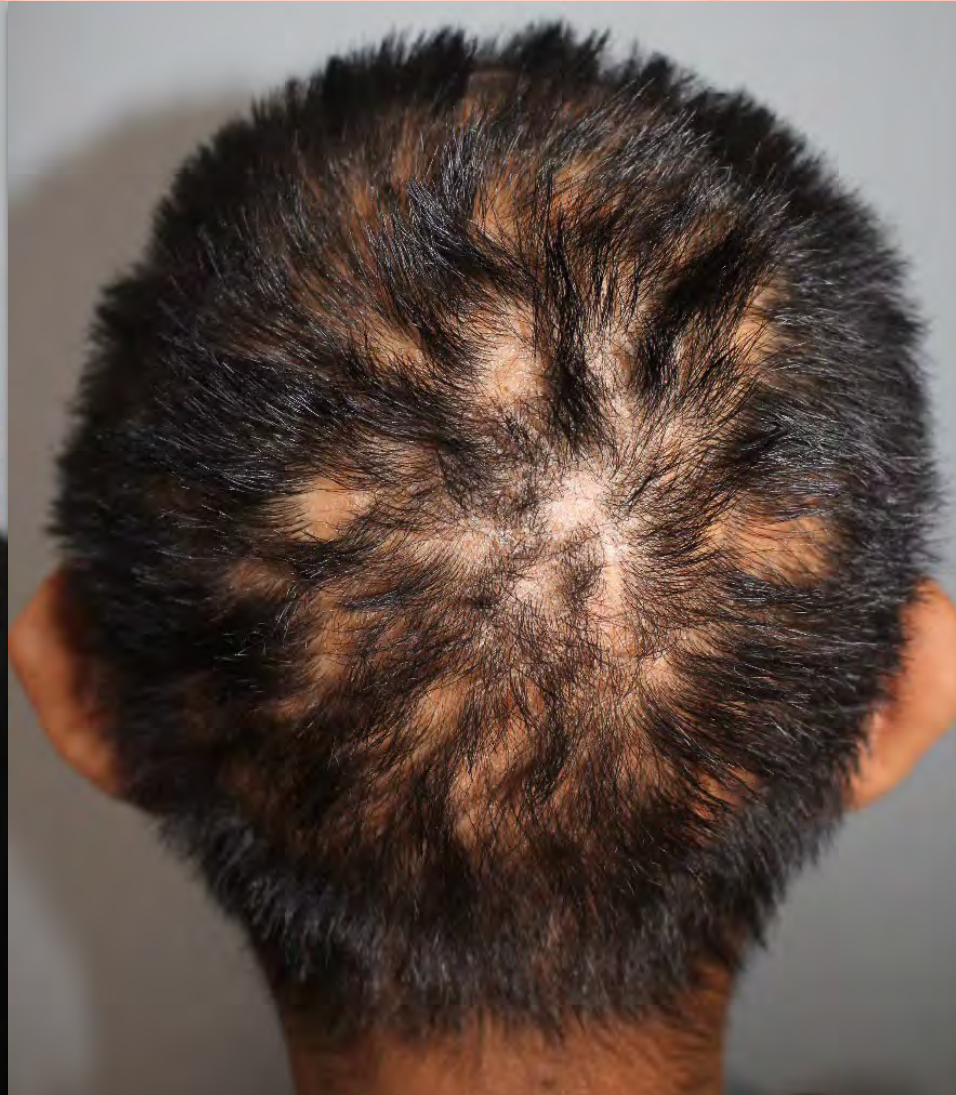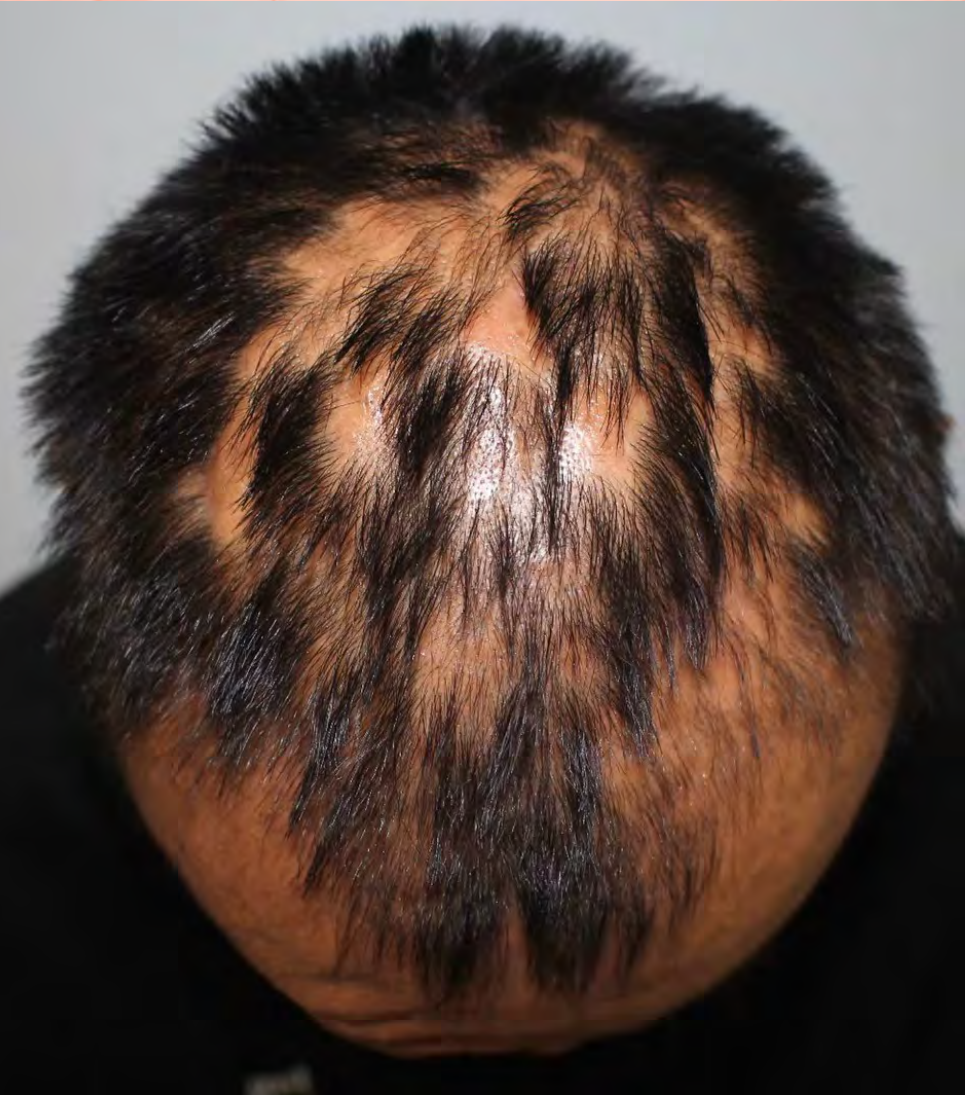HR : 81 bpm  
BP : 108/73 mmHg  
RR : 20 /min  
Temp : 36.3° c  
Height : 174 cm  
Weight: 59.5 kg

Physical examination of systems other than skin were within normal limit

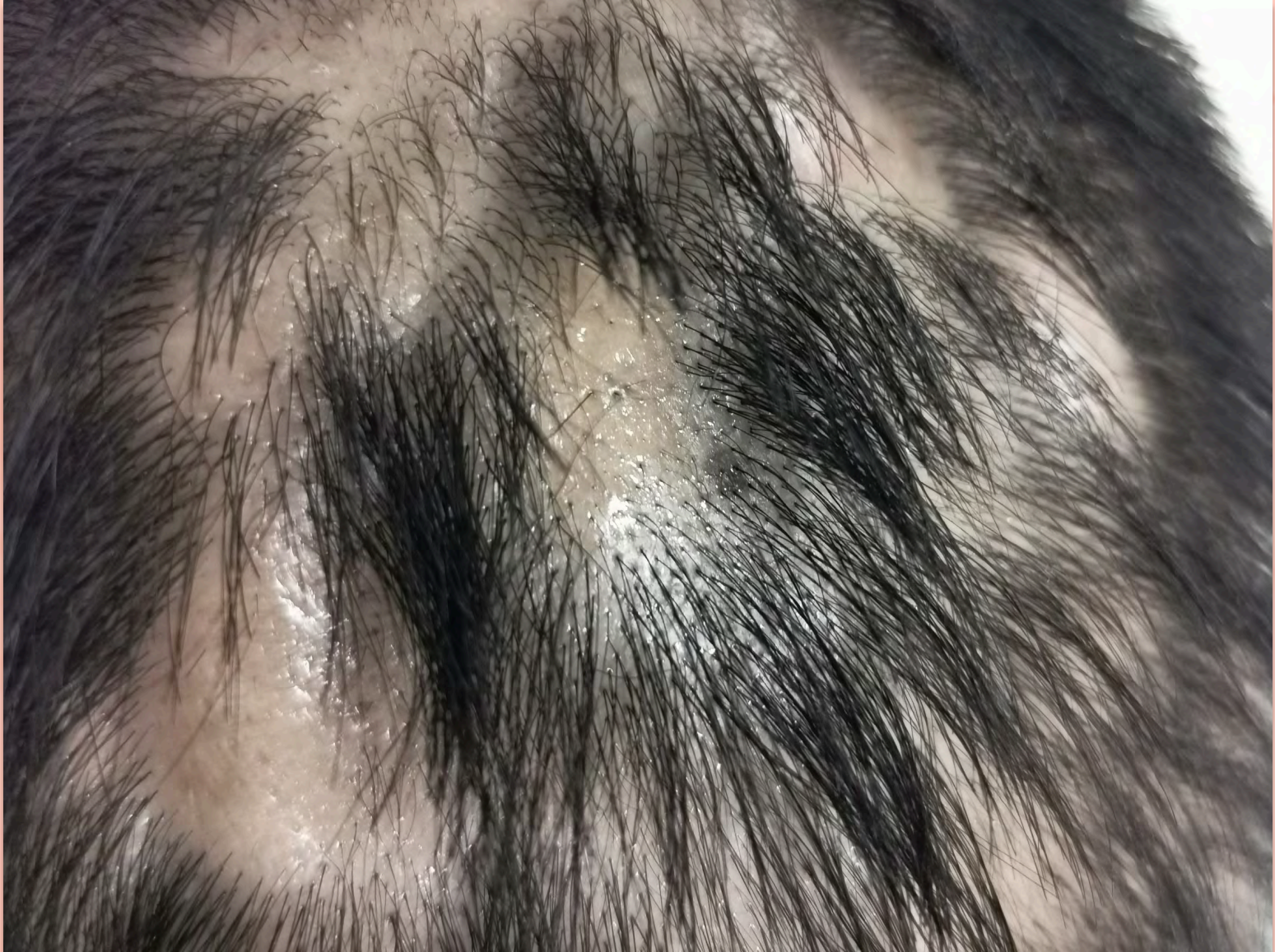Accentuated thick folded skin with deep furrows on forehead and nasolabial grooves



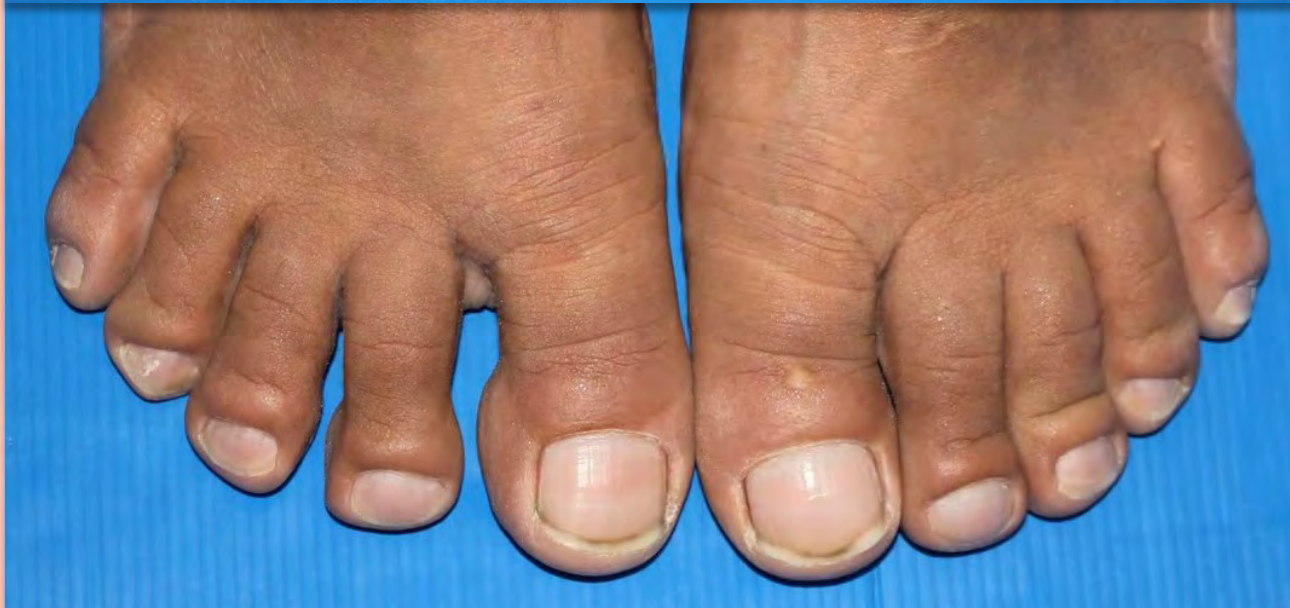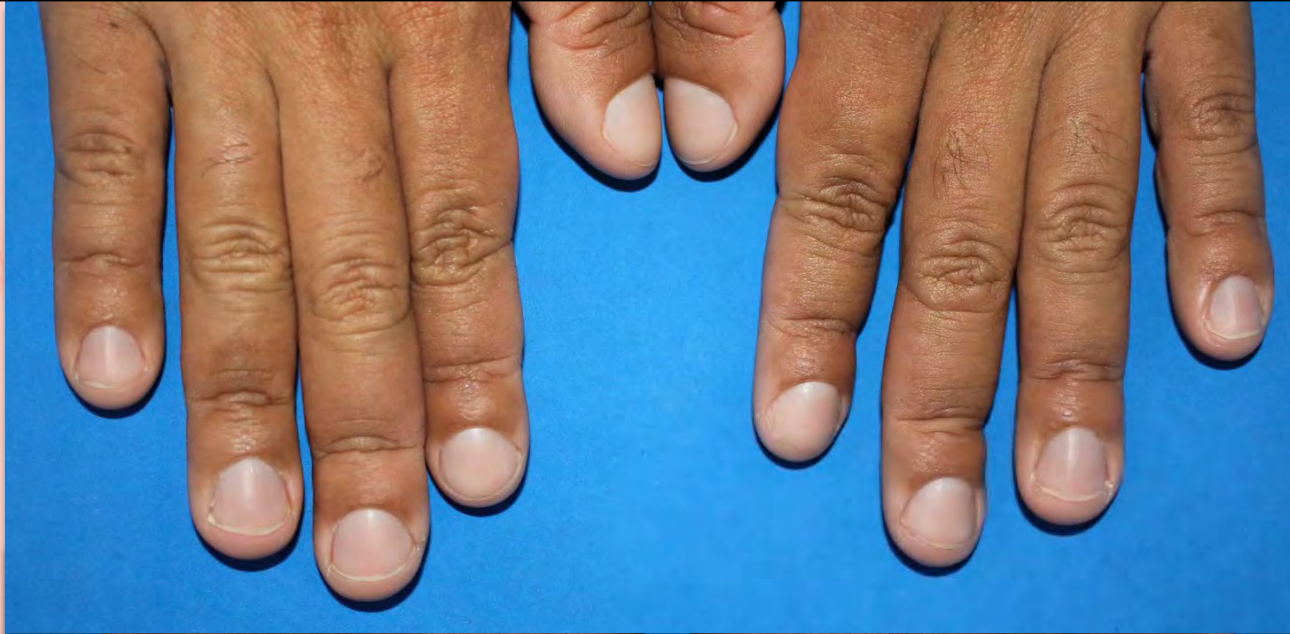# Multiple patchy scarring alopecia



# Cutis verticis gyrata



# Clubbing of fingers





# Problem list

- 1 Leonine face
- 2 Cutis verticis gyrata
- 3 Clubbing of fingers
- 4 Multiple patchy scarring alopecia

# Differential diagnosis

Leonine facies

Cutis verticis gyrata

Acromegaly

Lepromatous leprosy

Cutaneous T cell lymphoma

Hypertrophic osteoarthropathy  
(HOA)

Clubbing of fingers

Lung disease

Heart disease

GI disease

Thyroid disease

Hypertrophic osteoarthropathy  
(HOA)

# Differential diagnosis

Leonine facies

Clubbing of fingers

Cutis verticis gyrata

Acromegaly

Lung disease

Lepromatous leprosy

Heart disease

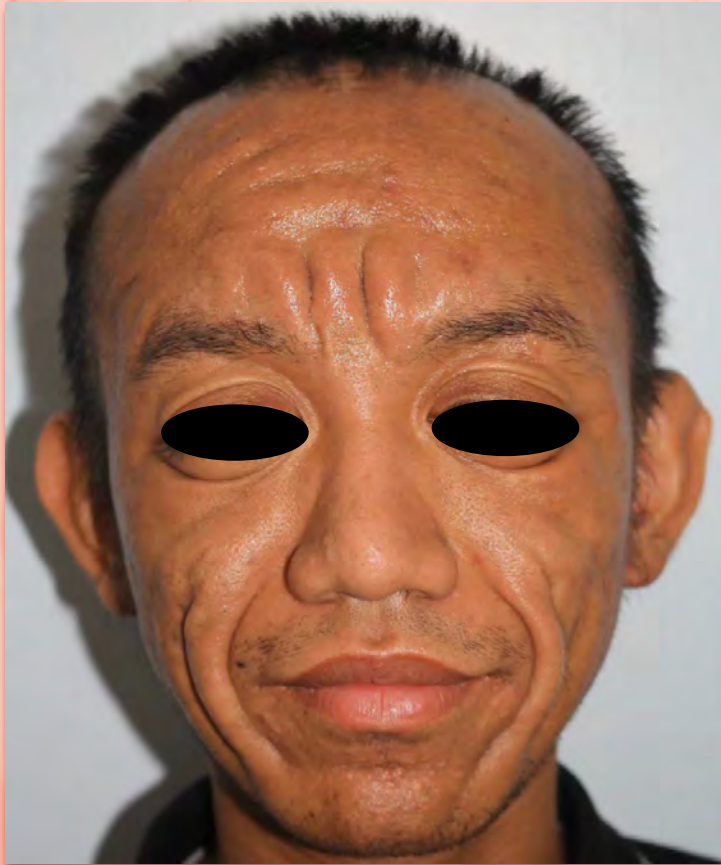Cutaneous T cell lymphoma

GI disease

Thyroid disease

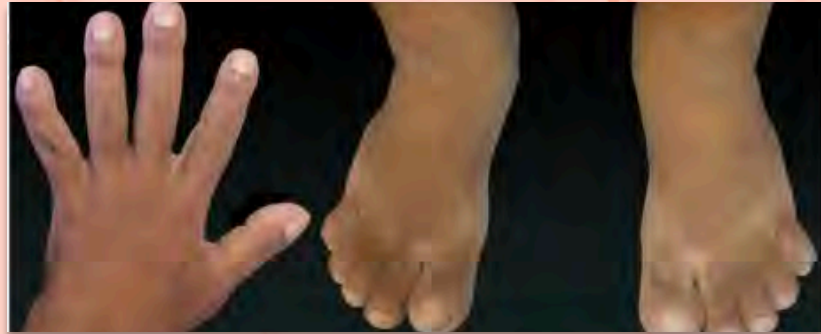**Hypertrophic osteoarthropathy (HOA)**

# Three main characteristics

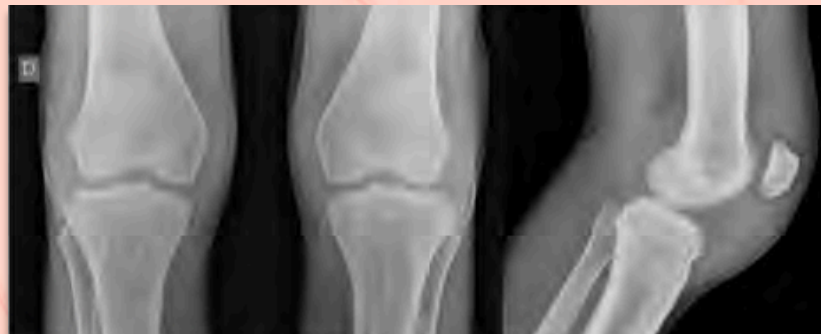

## Pachydermia

Thickening/furrowing on face & scalp



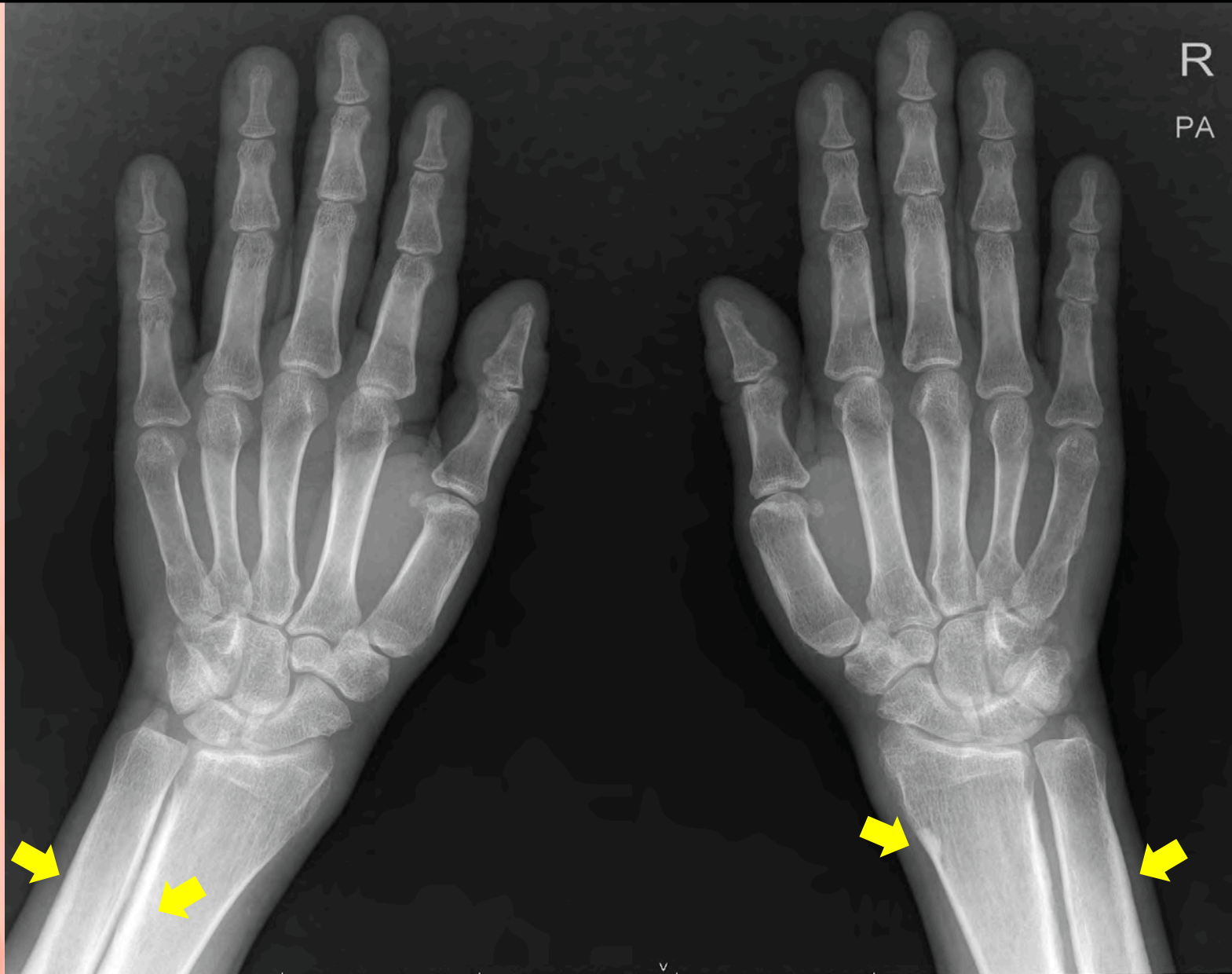
## Digital clubbing



## Periostosis

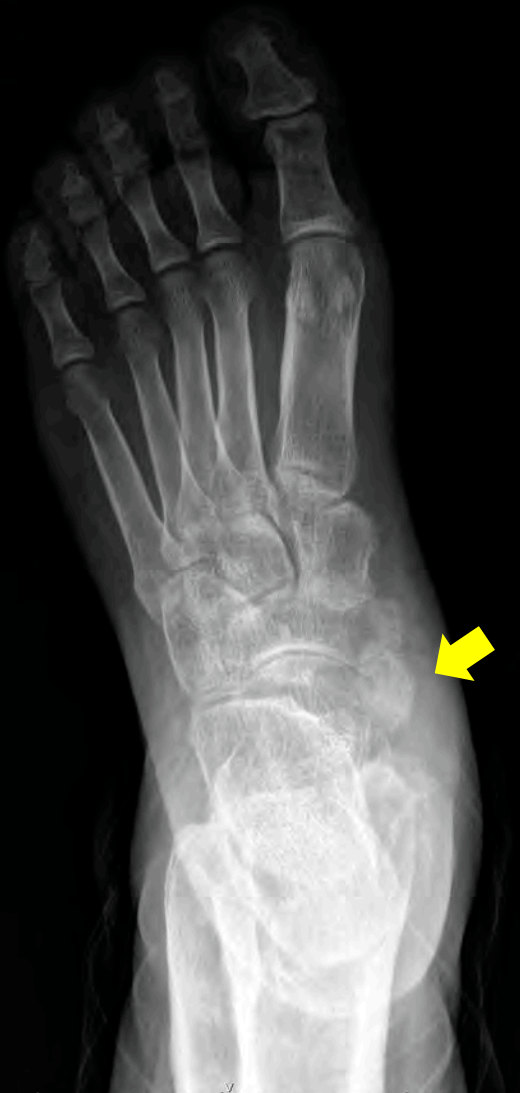Swelling of periarticular tissue  
periosteal formation of the long bones

# Symmetrical periosteal bone formation on several long bones and metatarsus

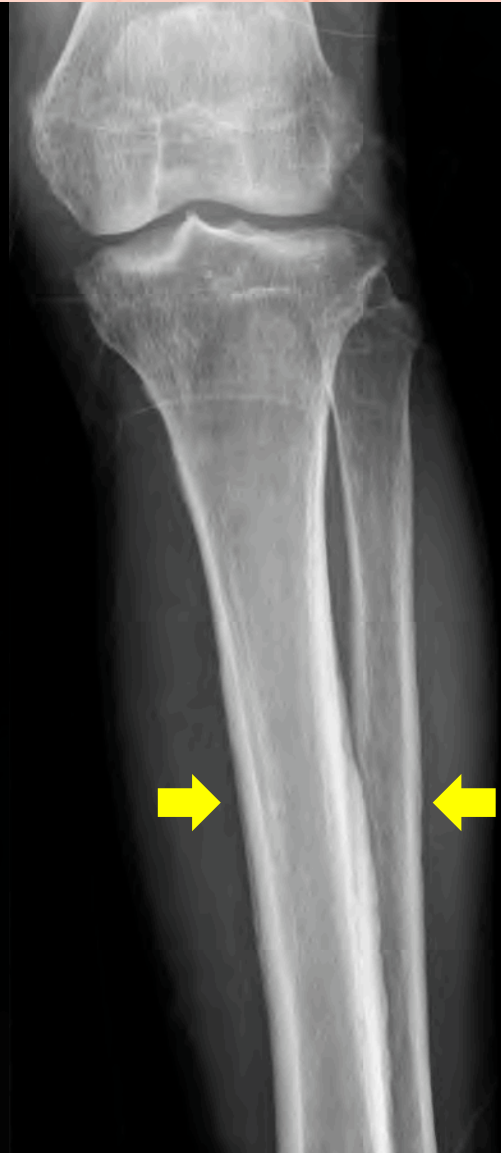

# Symmetrical periosteal bone formation on several long bones and metatarsus

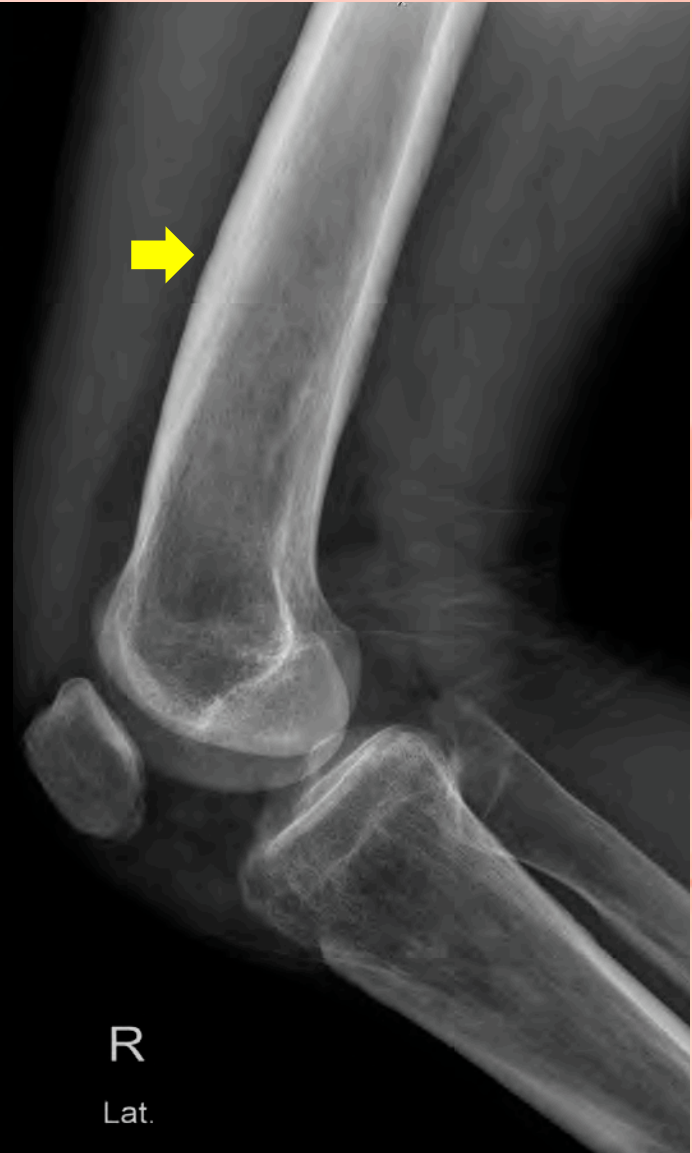L  
AP



L  
AP



R  
Lat.



# Hypertrophic osteoarthropathy (HOA)

## Primary HOA

Pachydermoperiostosis (Touraine-Solente-Gole syndrome)

## Secondary HOA

Cardiopulmonary disease

Malignancy

- Bronchogenic carcinoma  
(Pierre Marie-Bamberger syndrome)
- GI cancer
- Nasopharyngeal/esophageal cancer

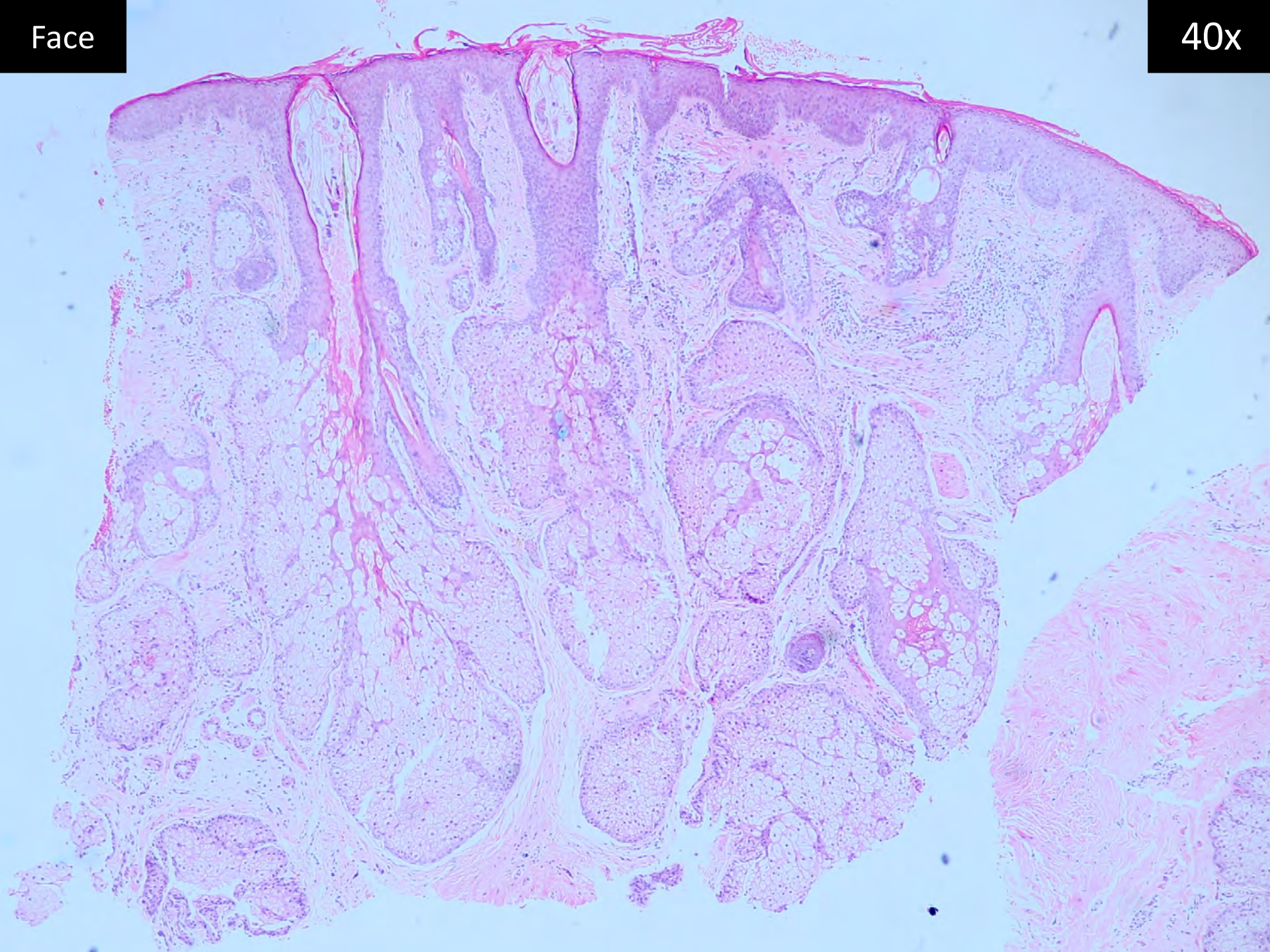
The background of the slide is a light orange or pinkish hue, featuring a faint, repeating pattern of microscopic tissue sections. These sections show elongated, wavy structures, possibly muscle fibers or connective tissue, with some darker, more concentrated areas that could be nuclei or specific cellular components. The overall appearance is that of a histological slide.

# Histopathology



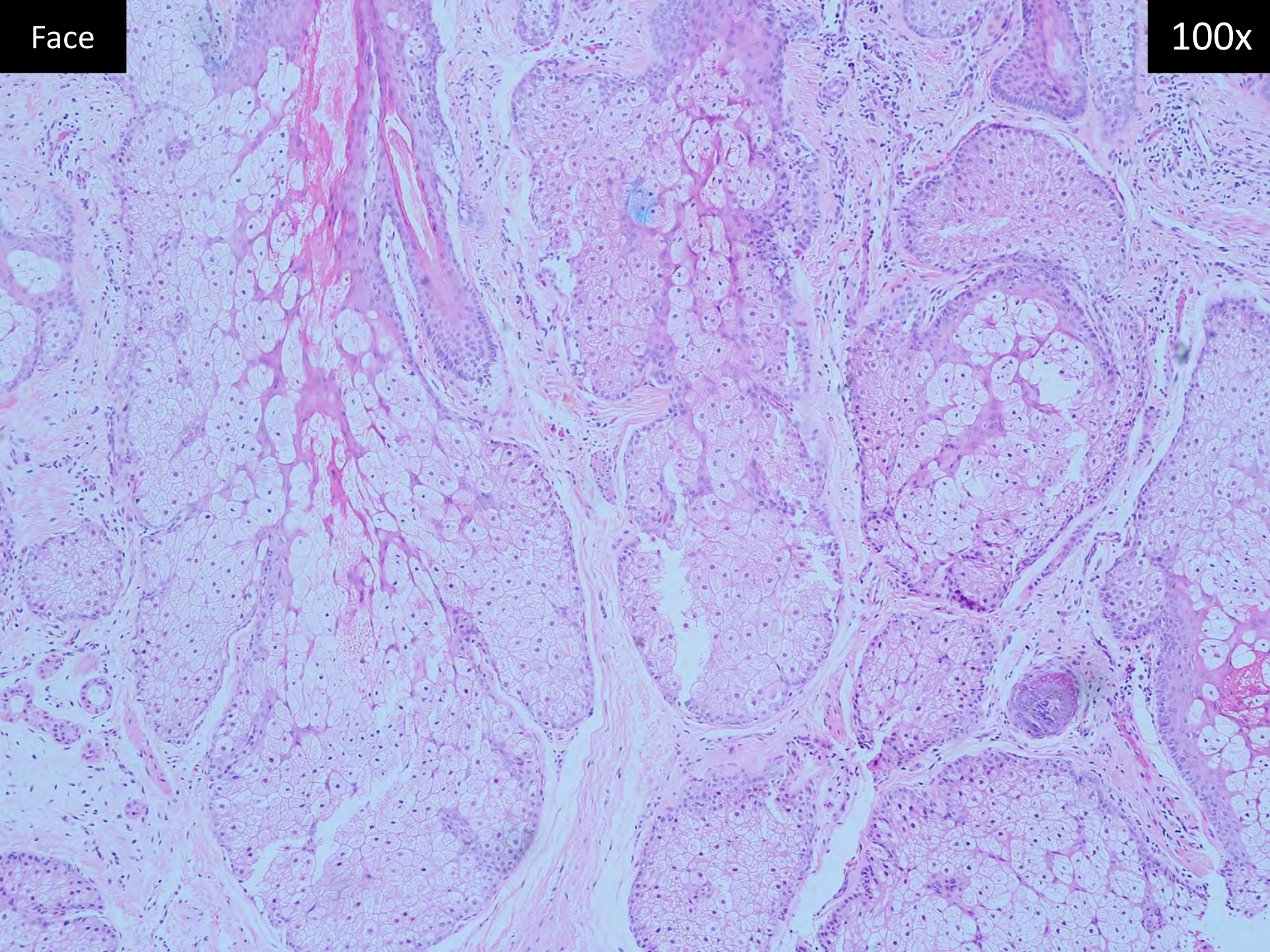
Face

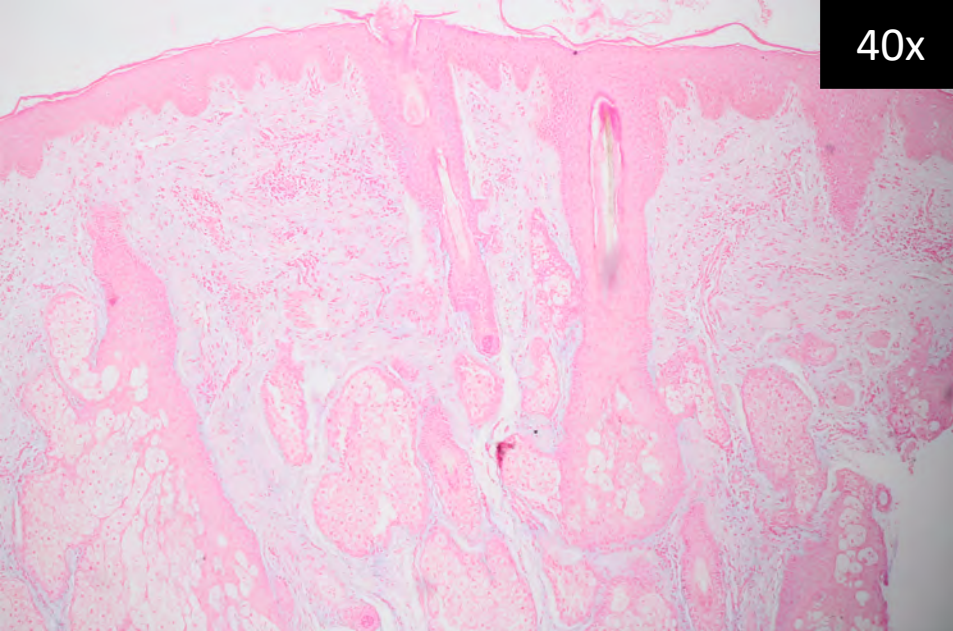
40x



Face

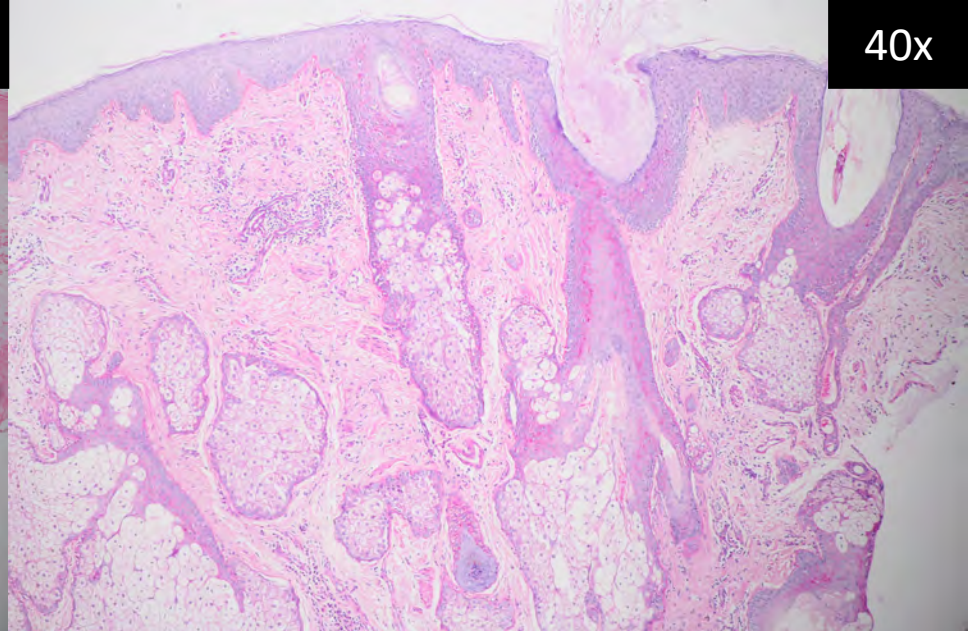
100x





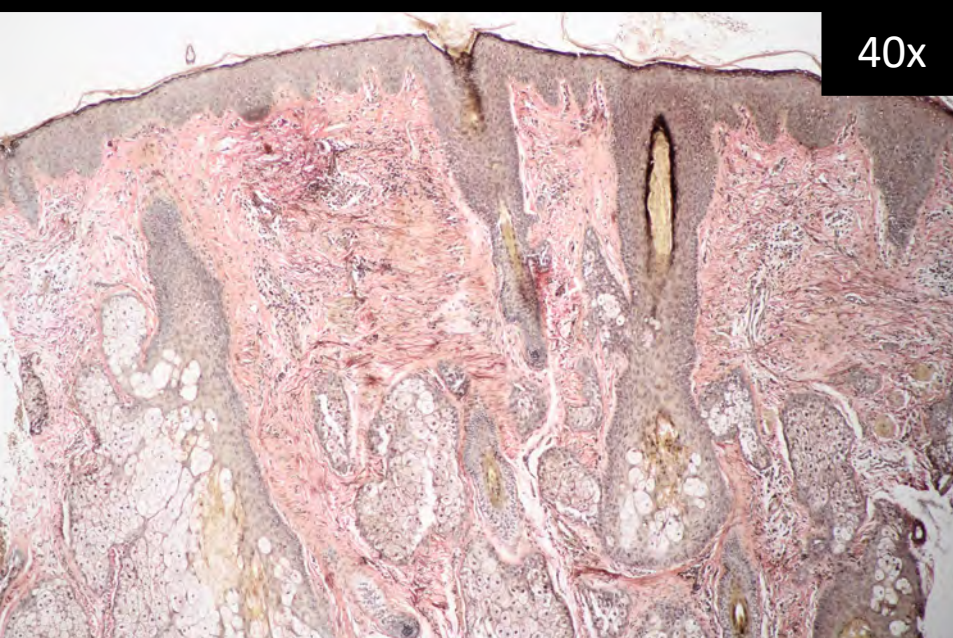40x

Alcian Blue



40x

PAS



40x

Voehoeff

### Special stain

Alcian Blue	:	not increase
PAS	:	normal
Voehoeff	:	normal

# Diagnosis



**Pachydermoperiostosis**



**Scarring alopecia from resolving folliculitis**

# Pachydermoperiostosis

Synonym: Primary hypertrophic osteoarthropathy (PHO),  
Touraine-Solente-Gole syndrome

Inherited in AD (few reported AR)

Onset 5-20 years

M:F = 9:1

Mutation of

- HPGD gene (Hydroxy-Prostaglandin Dehydrogenase)
- SLCO2A1 gene (Solute Carrier Organic Anion Transporter Family Member 2A1)

# Possible manifestations

## Joint involvement

- Arthritis
- Arthralgia
- Hydroarthrosis
- Hemarthrosis

## Other possible features

- Anemia
- Myelofibrosis
- Hypoalbuminemia
- GI abnormalities

## Cutaneous involvement

- Cutis verticis gyrata
- Seborrhea
- Hyperhidrosis of palms & soles
- Acne
- Erythematous lesions over joints
- Blepharoptosis
- Pole-like lower legs

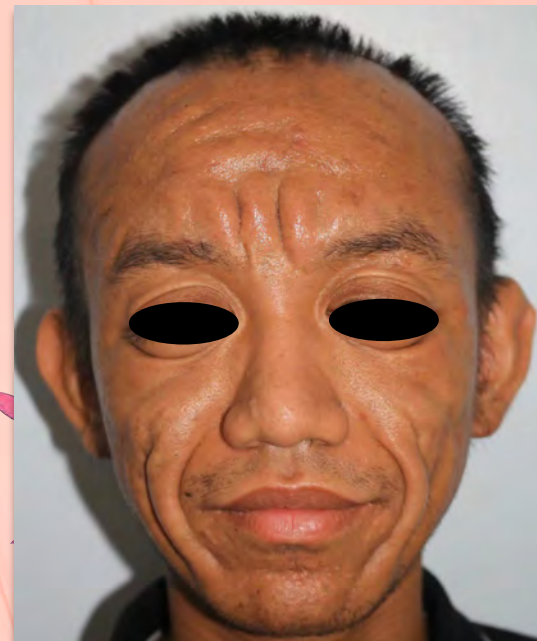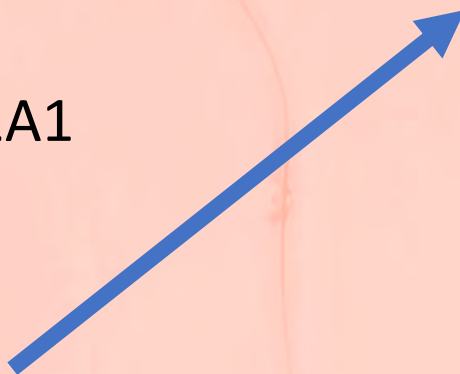
# Pathophysiology



HPGD  
or  
SLCO2A1



Impaired PGE2  
degradation



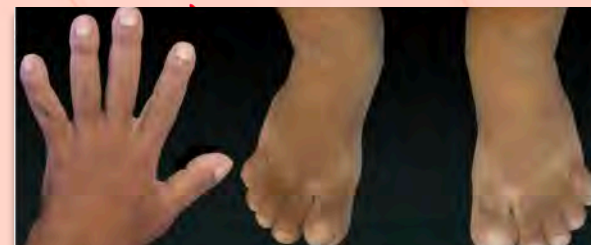
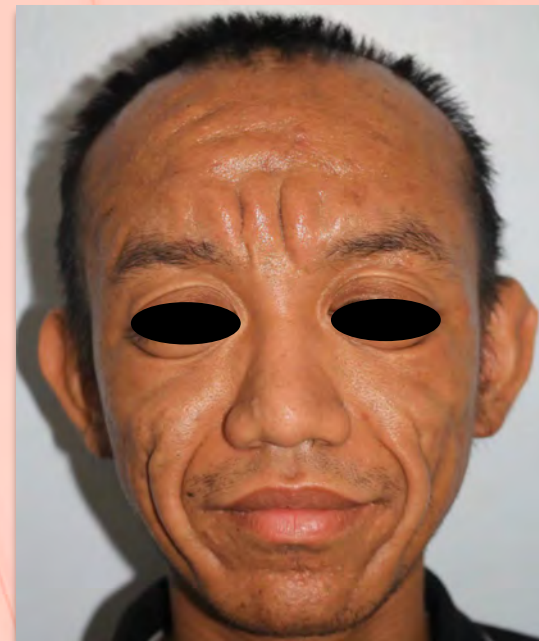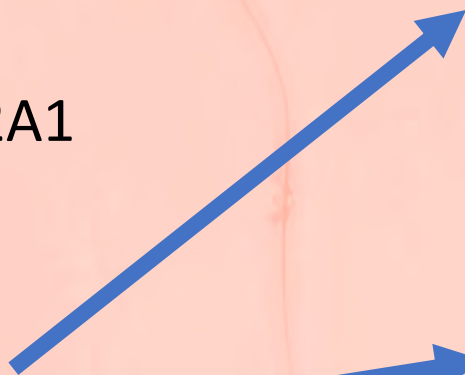
# Pathophysiology



HPGD  
or  
SLCO2A1



Impaired PGE2  
degradation





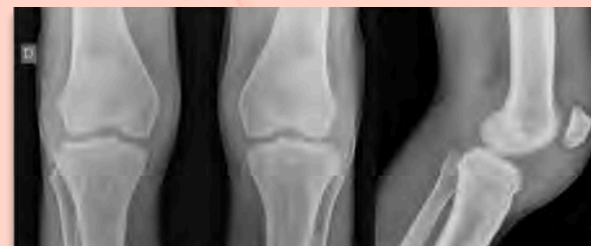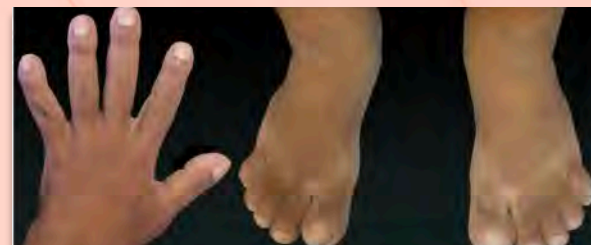
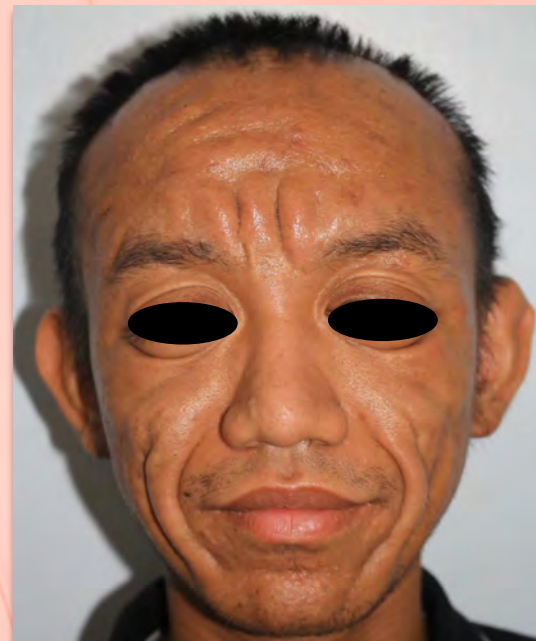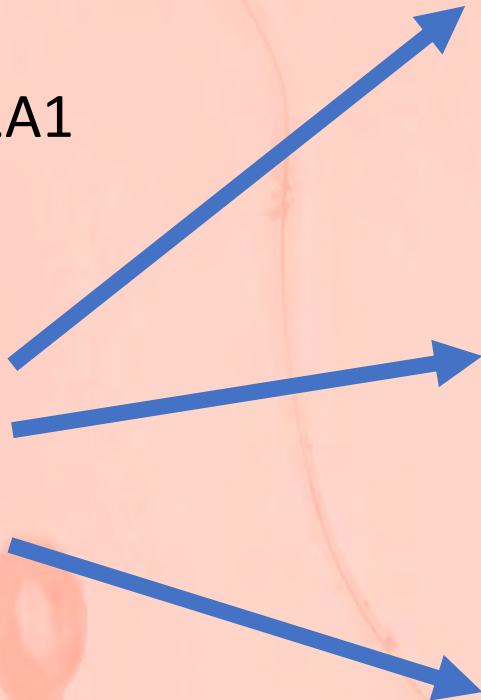
# Pathophysiology



HPGD  
or  
SLCO2A1



Impaired PGE2  
degradation



# Treatment

## SYMPTOMATIC TREATMENT

### Arthralgia/Arthritis

- NSAIDs
- Bisphosphonates
- Intra-articular steroid injection
- Colchicine
- Methotrexate
- Hydroxychloroquine
- Infliximab

### Hyperhidrosis

- Aluminum chloride

### Skin oiliness

- Oral isotretinoin

### Pachydermia

- Botulinum toxin injection
- Plastic surgery

# Treatment in our case

Isotretinoin (10) 1 tab PO OD

20% aluminum chloride lotion AP scalp & palms

Work up internal malignancy

**Consult clinical geneticist**

- HPGD, SLCO2A1 gene mutation

# Case summary

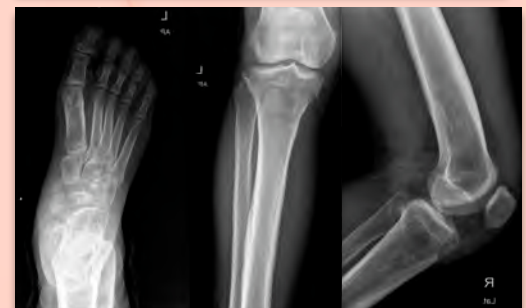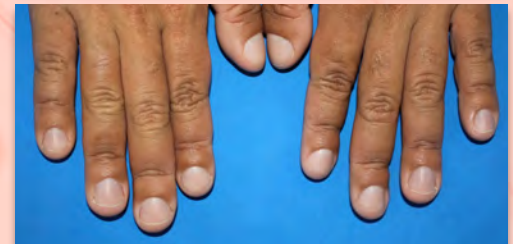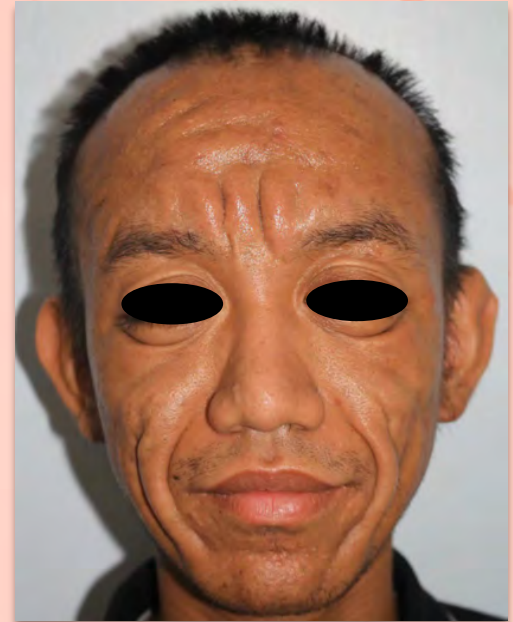**24-year-old male**

**CC:** chronic thickening and furrowing of skin, clubbing fingers, and scalp hyperhidrosis

**Dx:** Pachydermoperiostosis

**Tx:**

Hyperhidrosis	:	Aluminum chloride
SGH/Oily skin	:	Oral isotretinoin
Work up	:	malignancy, cardiopulmonary disease, genetic mutation



## Take home message

# Pachydermoperiostosis

Pachydermia + digital clubbing + periostosis

HPGD or *SLCO2A1* gene mutation

Always rule out secondary cause especially internal malignancy