



# **Interhospital Conference**

## **Case 3**

**Pimsiri Anansiripun, MD**

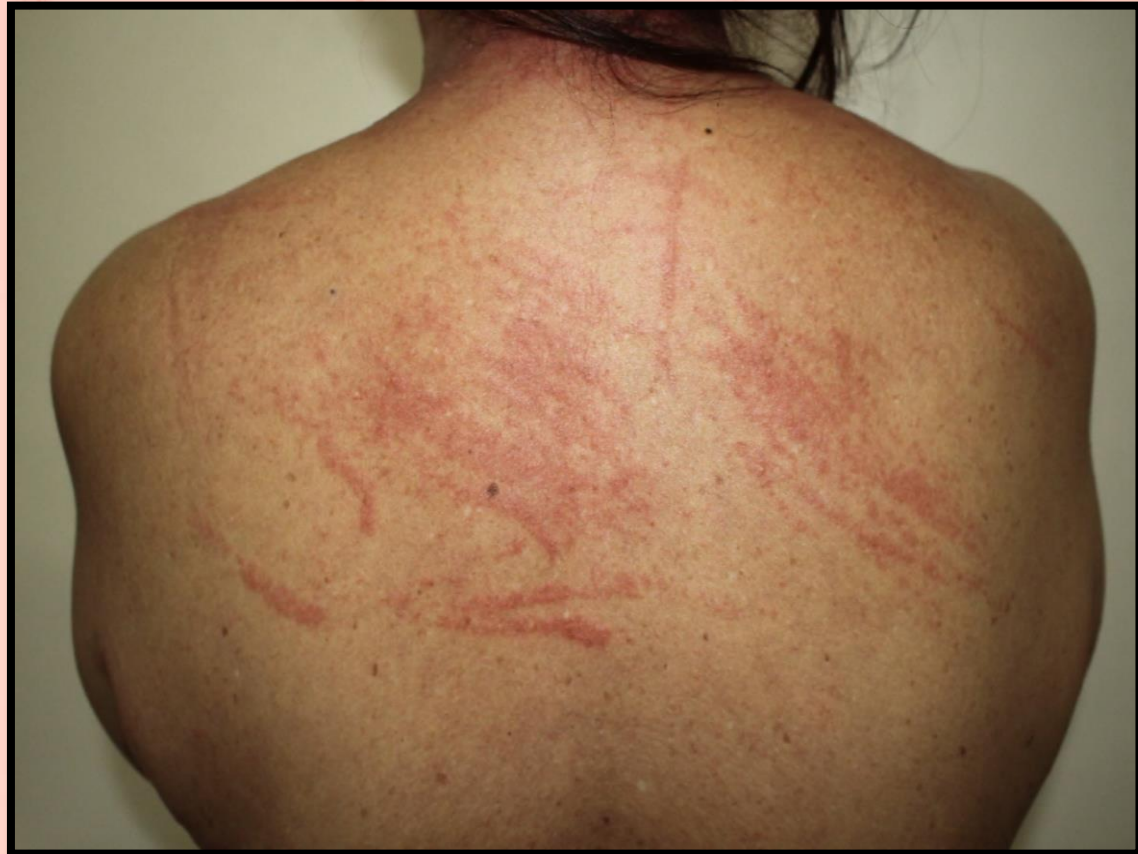**Jutamas Tankunakorn, MD**

**Somsak Tanrattanakorn, MD**



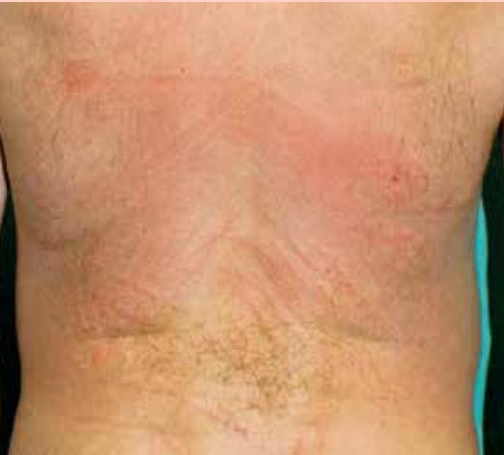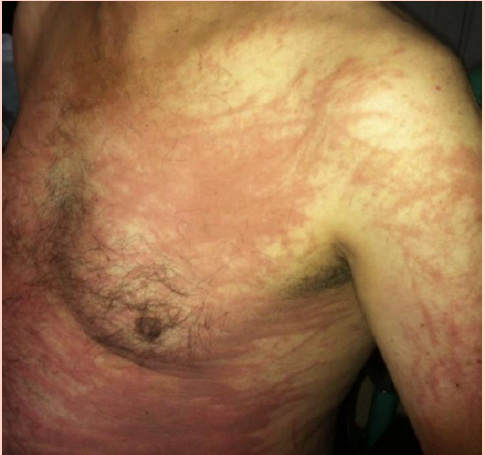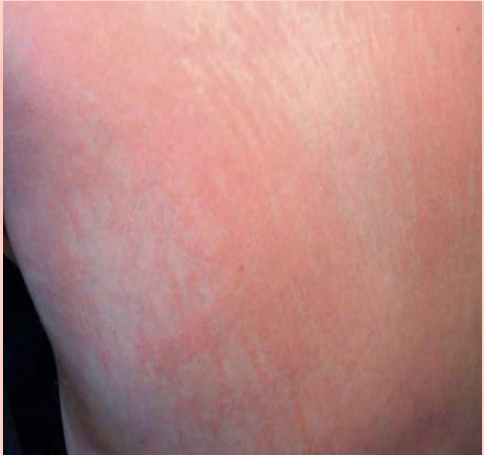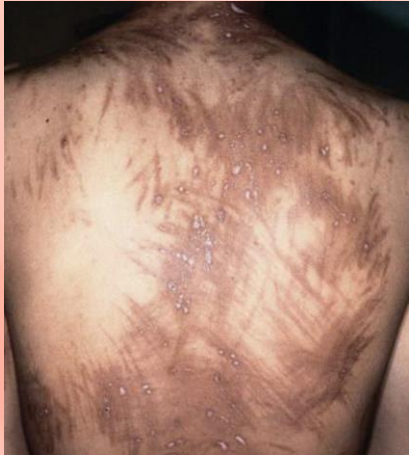# A 73-year-old Thai female

**Generalized  
flagellate erythema  
for 3 days**



# Differential diagnosis

## Flagellate erythema



**Drug**

**Dermatomyositis**

**Adult-onset  
Still disease**

**Shiitake dermatitis**

- |                  |              |              |
|------------------|--------------|--------------|
| <b>Bleomycin</b> | Bendamustine | Peplomycin   |
| 5-Fluorouracil   | Docetaxel    | Transtuzumab |

# Present illness

- 3 days ago, the patient ate full plate of steamed mushrooms with soy sauce
- 2 days later, she developed generalized itchy erythematous flagellate rash
- No fever, no fatigue

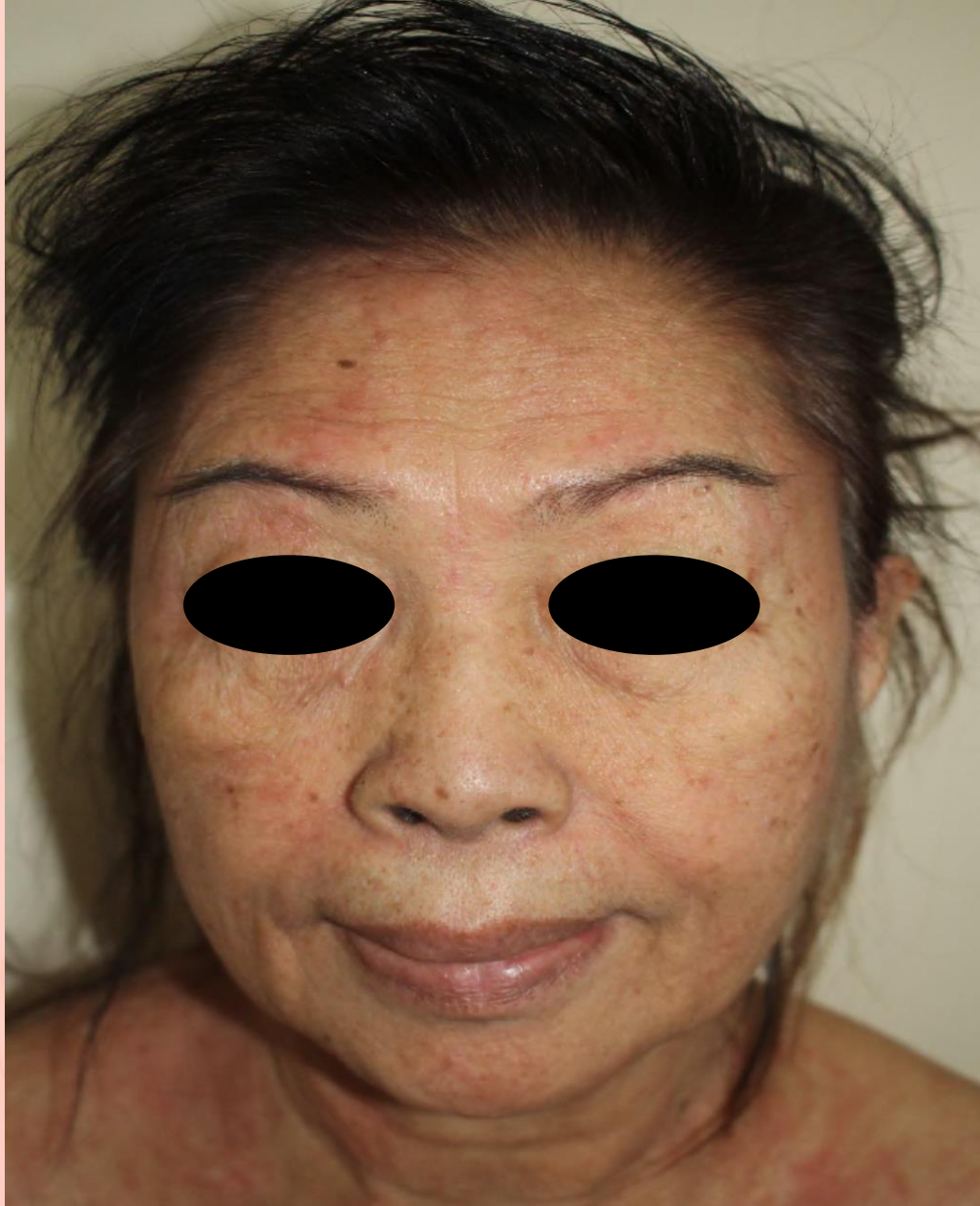# Past history

- **Comorbidities:** HTN, DLP, T2DM
- **Current medications:**
  - Amlodipine 5mg po od
  - Atorvastatin 40 mg po od
  - Enalapril 20 mg po od
  - Metformin 850 mg po od

# Physical examination

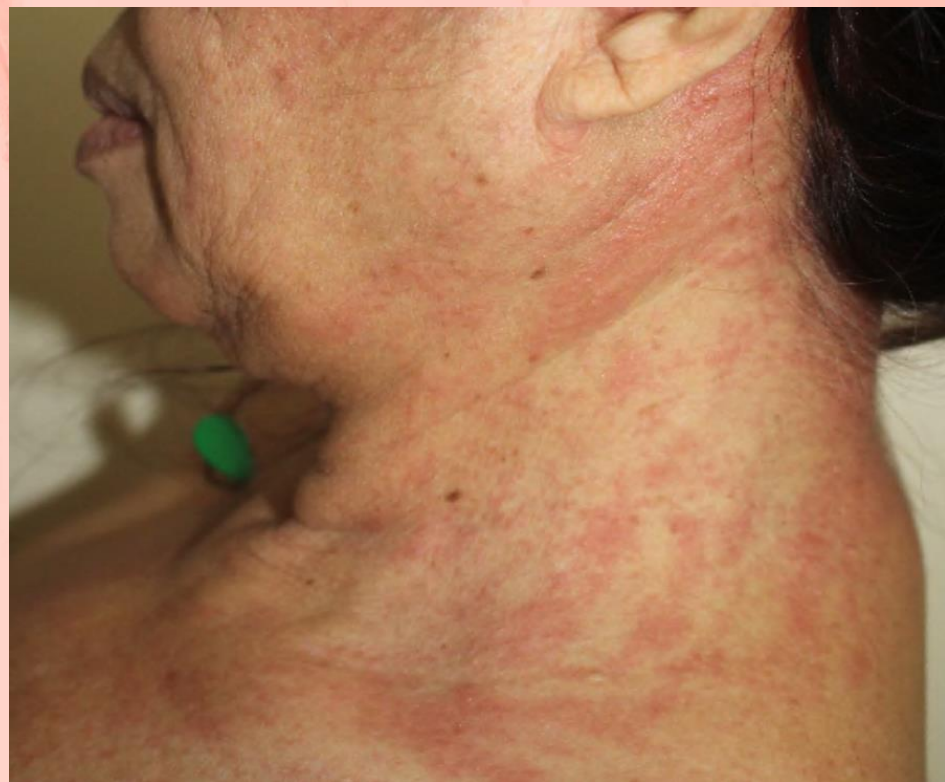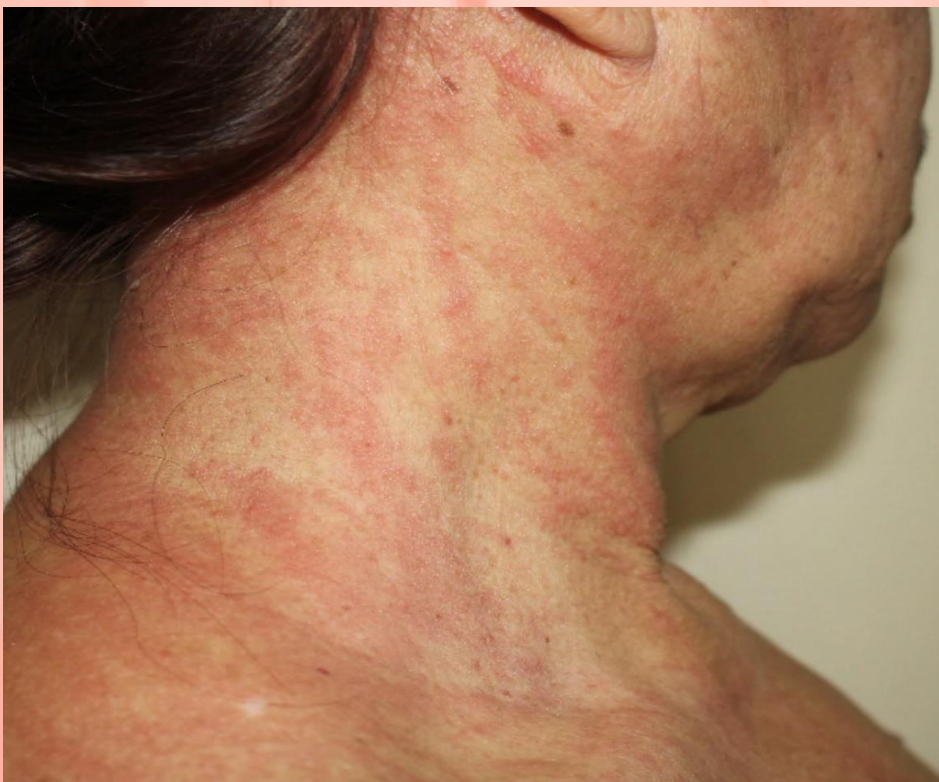- **V/S:** HR 91 bpm, **BP 156/97 mmHg**, RR 20/min, Temp 37°c
- **HEENT:** no pale conjunctivae, no icteric sclera, no lymph node enlargement
- **Lungs:** WNL
- **CVS:** WNL
- **Abd:** soft not tender, liver and spleen can't be palpated
- **Neuro:** WNL
- **Ext:** no pitting edema

# Dermatological examination

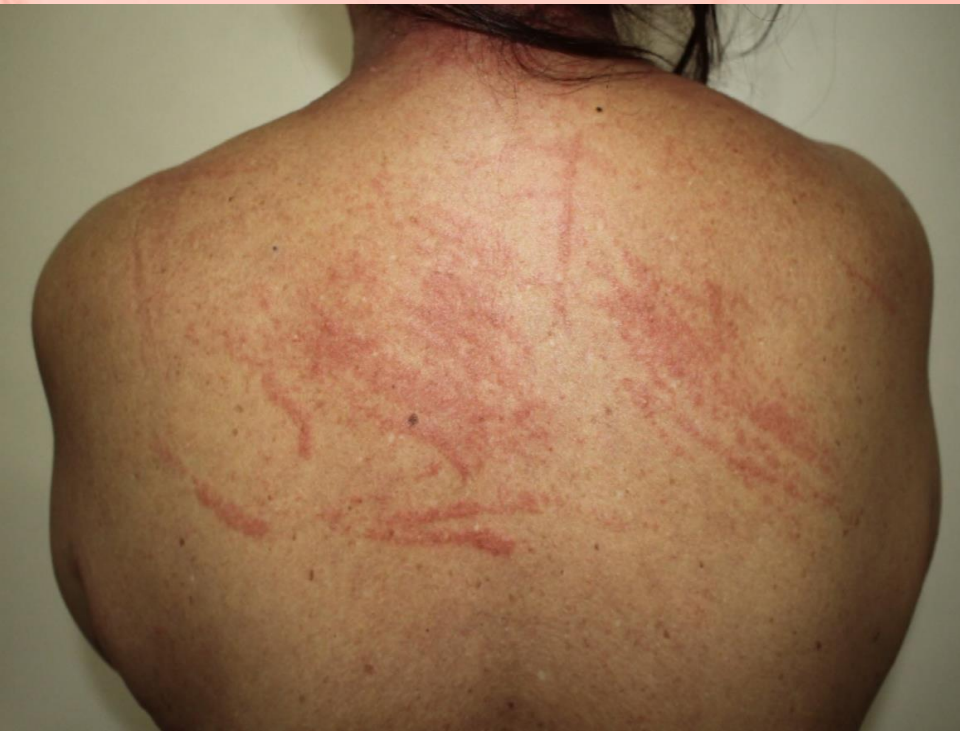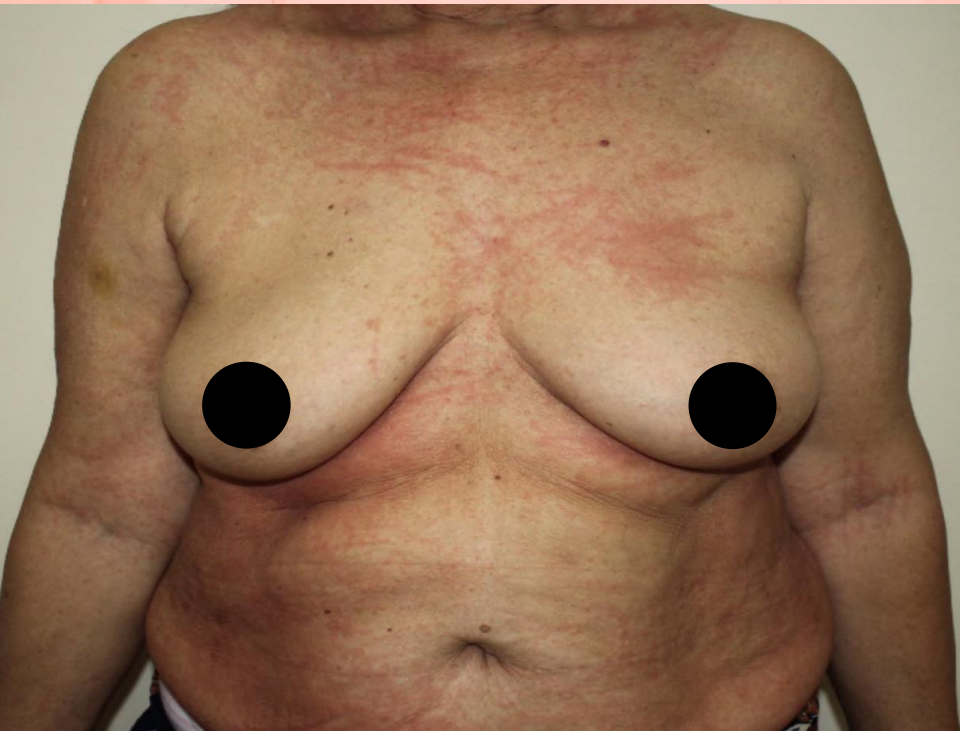


Generalized erythematous papules and plaques arranged in flagellate streaks on face

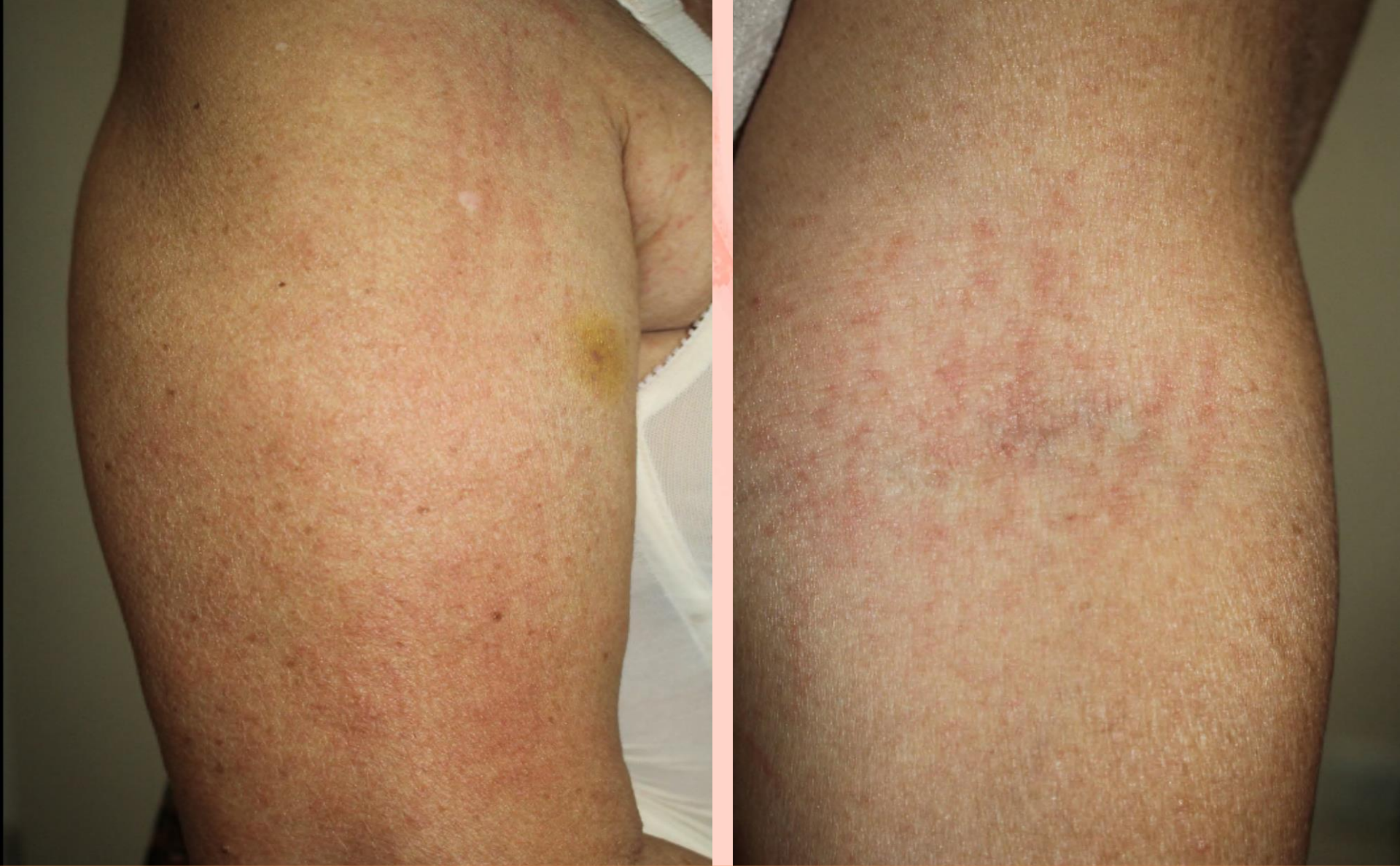



Generalized erythematous papules and plaques arranged in flagellate streaks on neck



Generalized erythematous papules and plaques arranged in flagellate streaks on trunk



Generalized erythematous papules and plaques arranged in flagellate streaks on extremities  
Dermographism: negative

# Problem list

- Generalized flagellate erythema for 3 days
- History of mushroom ingestion
- Comorbidities: HTN, DLP, T2DM

# Diagnosis

Shiitake dermatitis

# Management

- Prednisolone 20 mg po od x 5 days
- Cetirizine 10 mg po bid
- Hydroxyzine 10 mg po hs
- 0.1% triamcinolone lotion apply lesions bid

# Shiitake dermatitis

# Shiitake mushrooms (*Lentinus edodes*)

Bunashimeji – เห็ดโคน

King oyster mushroom –  
เห็ดนางรมหลวง

Enokitake – เห็ดเข็มทอง

Shiitake - เห็ดหอม





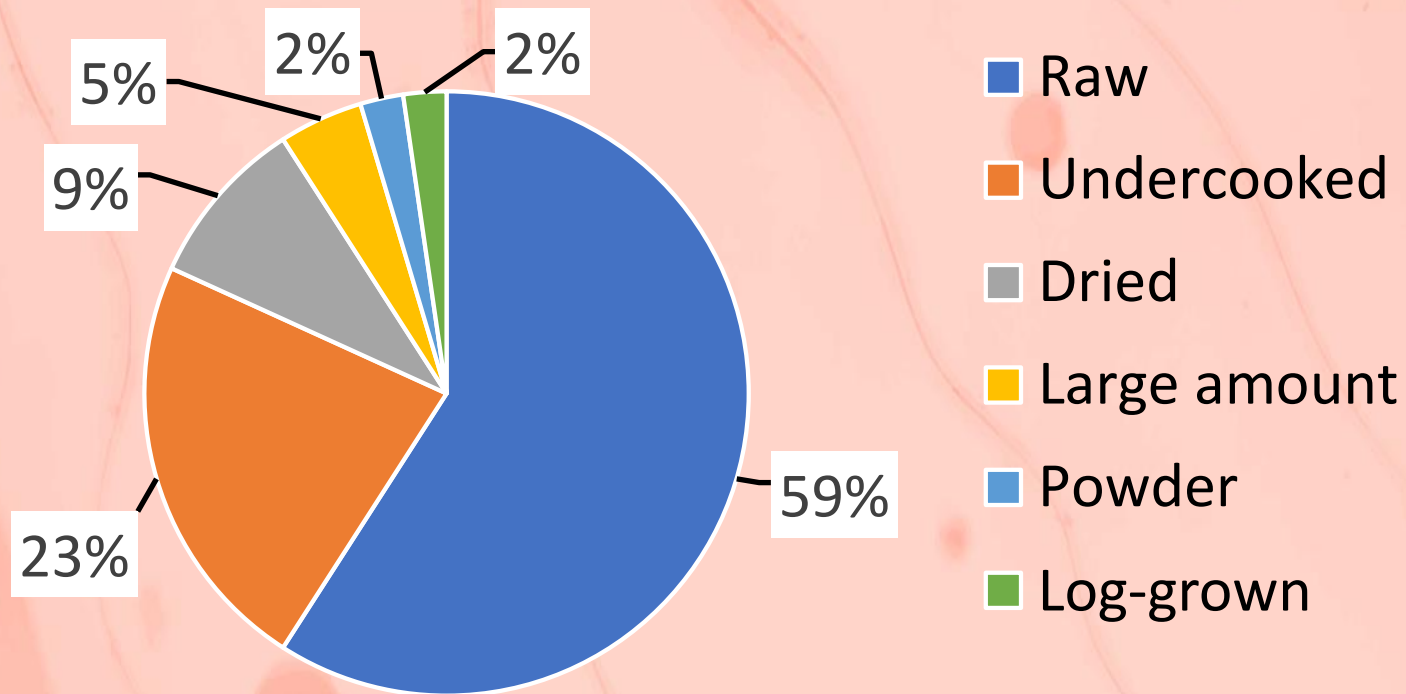
# Shiitake dermatitis



- **Cause:** ingested raw or undercooked shiitake mushrooms
- **Clinical:** flagellate erythema
- **Location:** trunk and extremities
- **Onset:** 24–48 h after ingestion
- **Prognosis:** spontaneous regression

**No life-threatening systemic reactions**

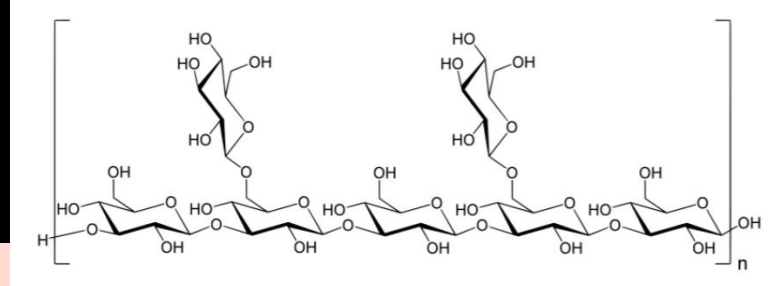
# Type of ingested mushrooms



**Contact dermatitis from shiitake mushroom had also been reported**

Int J Dermatol. 2017;56:610-6.  
 Australas J Dermatol. 2003;44:155-7.  
 J Eur Acad Dermatol Venereol. 2016;30:197-8.

# Pathogenesis



- **Lentinan** (Polysaccharide in mushroom cell wall)
  - Thermolabile toxin
  - Heat at 130–145°C destructs hydrogen bonds
  - Inadequately cooked mushroom causes eruptions
  - Amount of ingested mushroom that caused rash is vary
  - Adjuvant therapeutic drug for treating cancers

Int J Dermatol. 2017;56:610-6.

Postepy Dermatol Alergol. 2014;31:187-190.

J Eur Acad Dermatol Venereol. 2015;29:1449-51.

# Mechanism: unclear

Toxic reaction

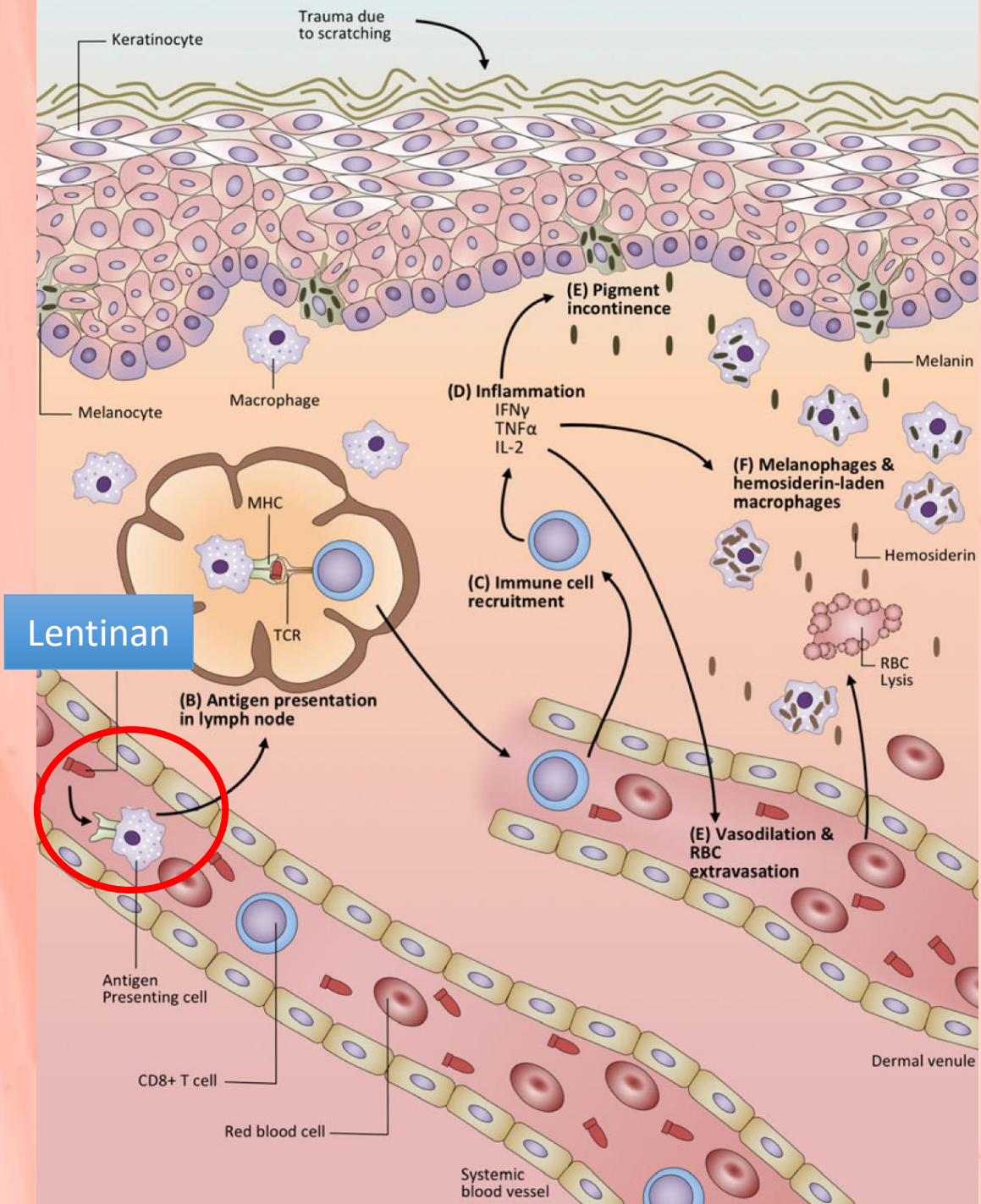
Hypersensitivity type 4



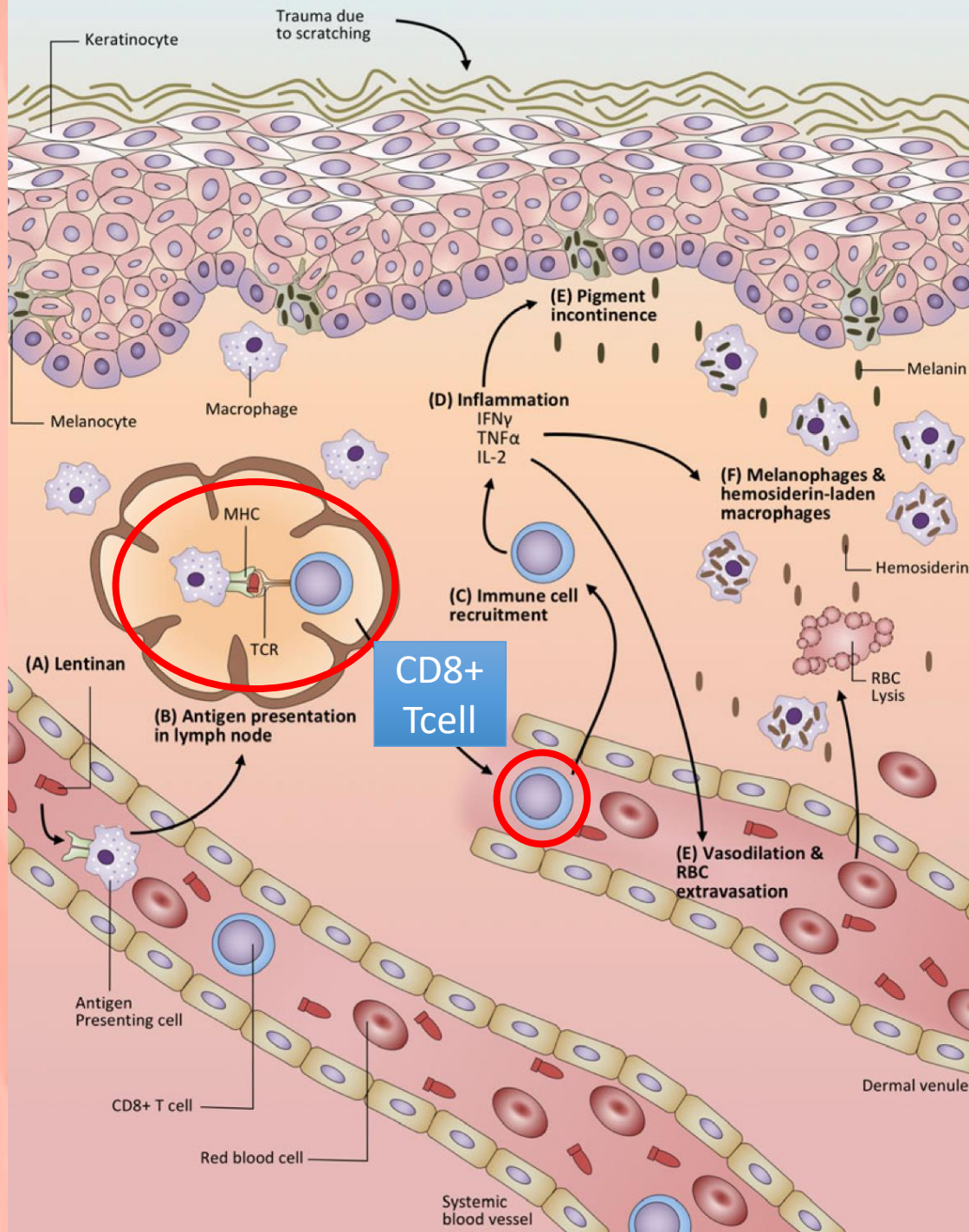
IV Lentinan



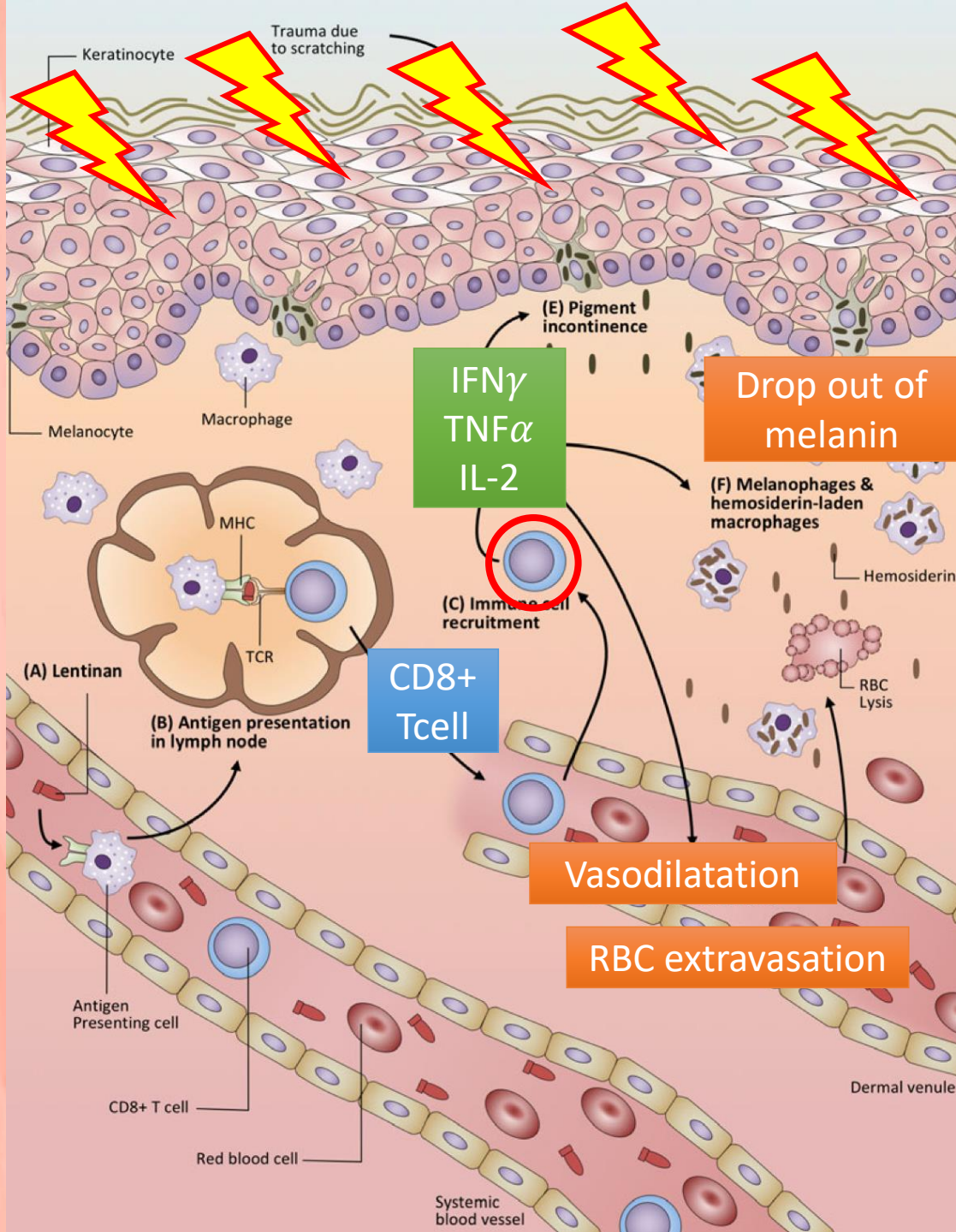
**Flagellate erythema 1.73% (9/519)**



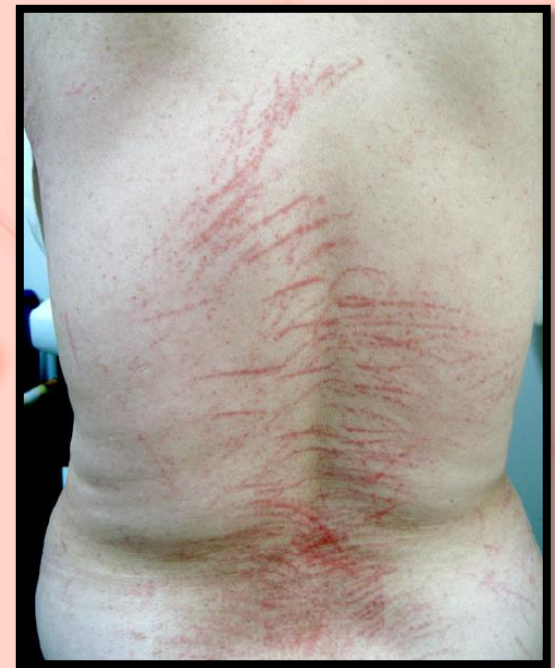# Hypersensitivity type 4 in shiitake dermatitis



## Hypersensitivity type 4 in shiitake dermatitis



## Hypersensitivity type 4 in shiitake dermatitis



# Diagnosis

- Clinical diagnosis
  - Specific tests were not frequently performed
    - Prick test:
    - Patch test:
    - Oral rechallenge:
    - Histology: variable and not specific
- } negative



# Treatment

- Symptomatic treatment
  - Topical corticosteroids
  - Oral antihistamines
- Resolution within 1 - 8 weeks
  - If mushrooms are avoided

# Prevention

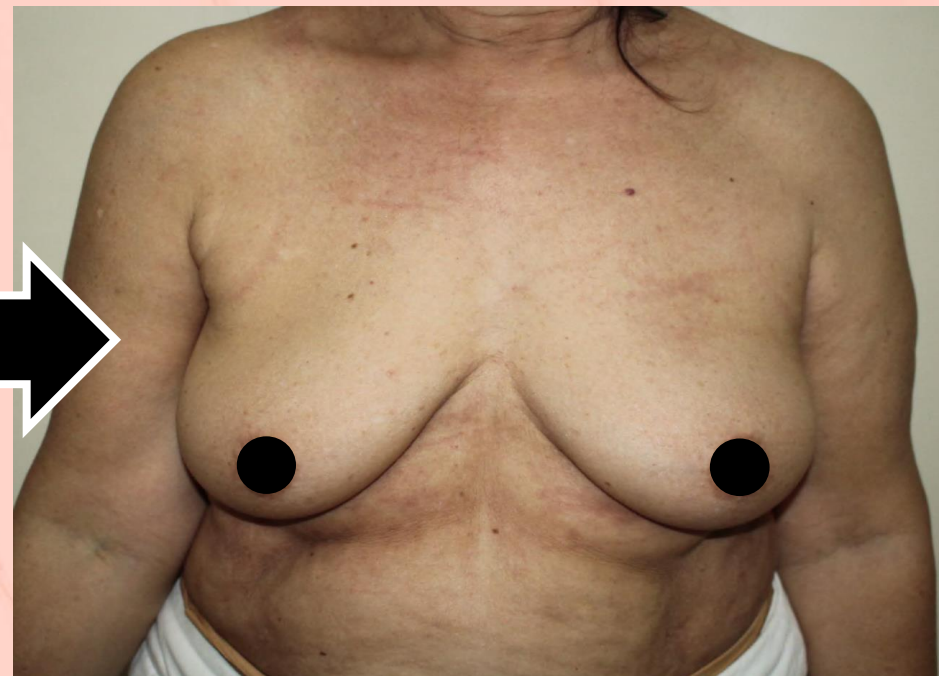
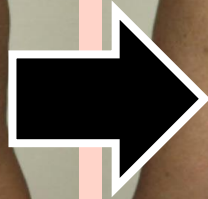
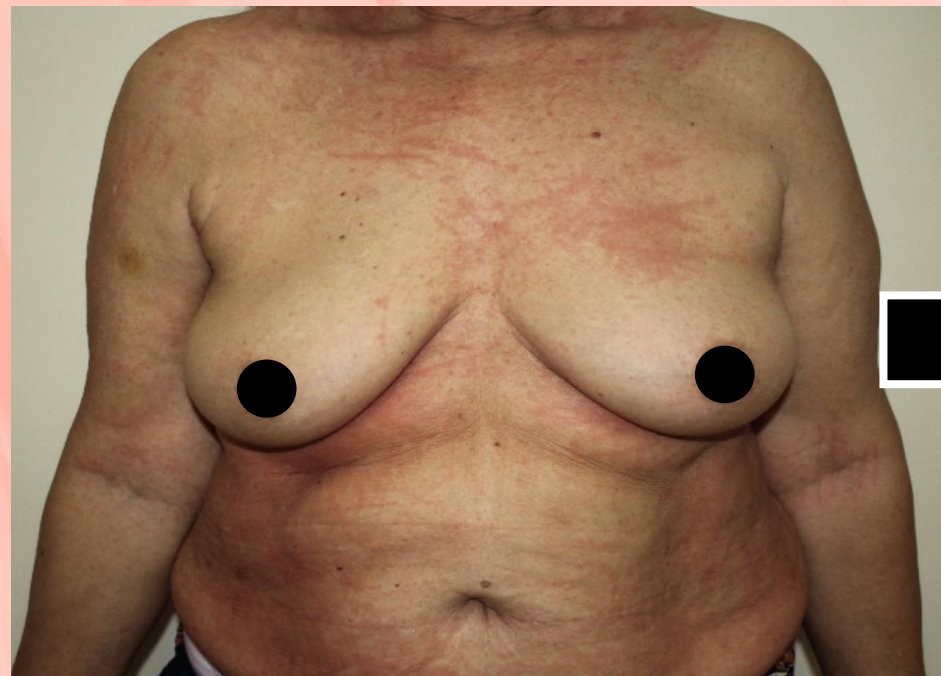- Re-exposure to lentinan can cause eruption
- Consuming shiitake mushroom cooked over 150°C for at least 15 mins is suggested



# Clinical follow-up

17 June 2020

24 June 2020



# Case summary

73-year-old female with generalized flagellate erythema for 3 days

**Dx:** Shiitake dermatitis

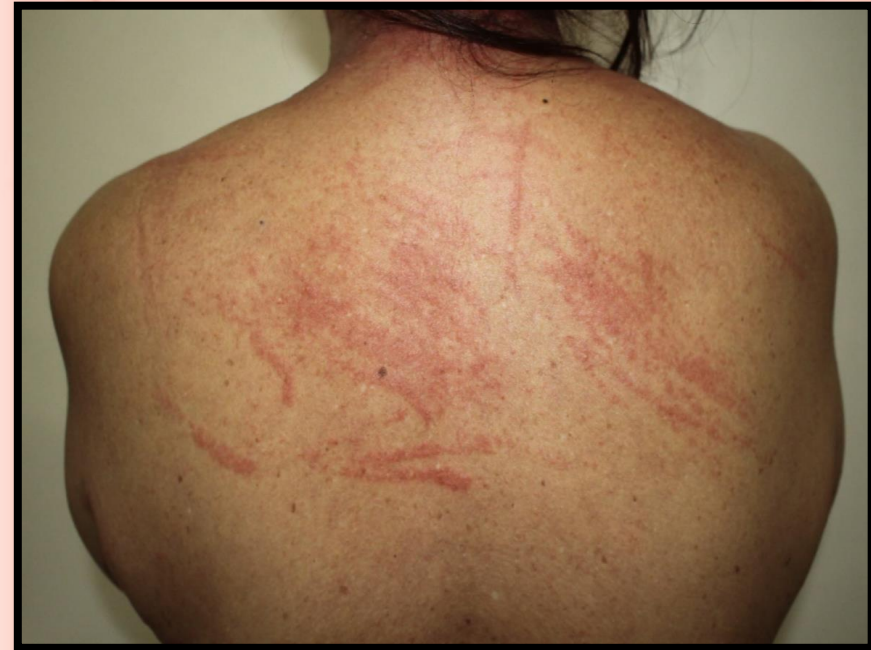**Rx:** - Prednisolone

20 mg/day x 5 days

- Hydroxyzine

- Cetirizine

- Topical steroids



# Take home message

## Shiitake dermatitis

Dose not occur in every person  
who ingested shiitake mushroom

Increased risk with large amount of ingestion

**Prevention:** consuming adequately cooked mushrooms  
( $> 150^{\circ}\text{C}$  for at least 15 mins)