



Interhospital Conference

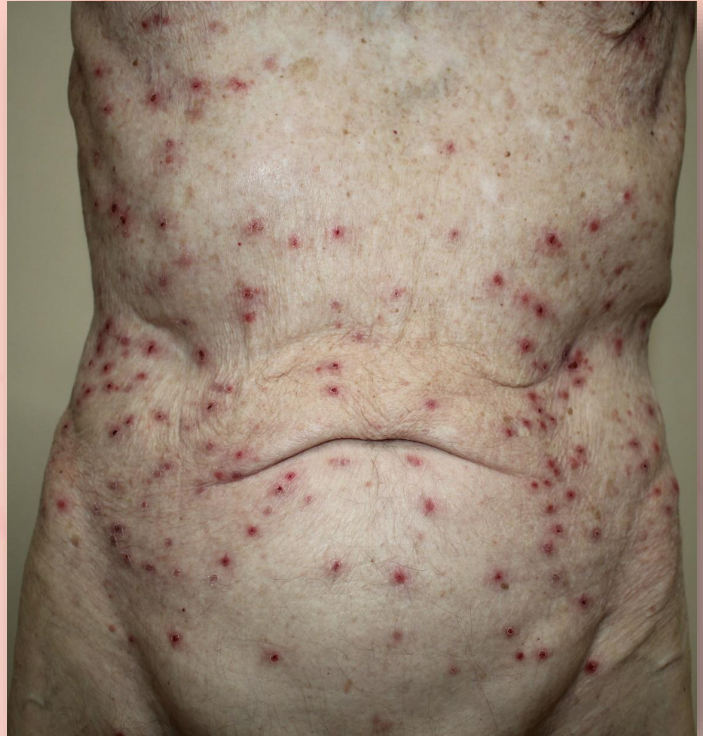Case 5

Kallapan Pakornphadungsit, MD
Suthinee Rutnin, MD



A 79-year-old Caucasian male

Pruritic rashes on trunk for 2 weeks



Present illness

2 weeks earlier,

- Pruritic erythematous rashes on upper abdomen and spread to lower abdomen & lower back
- No history of fever
- Unknown aggravating factors

Past history

SCC Lt. parotid gland
S/P total parotidectomy with
LN dissection & adjuvant RT

SCC base of tongue S/P RT

2001

2007

2018

2019

multiple NMSC S/P excision

Personal history

Comorbidities:

- HTN, DLP, BPH

Current medications:

- Simvastatin 10 mg/d PO
- Verapamil 80 mg/d PO

Family history

- No history of similar symptoms

Physical examination

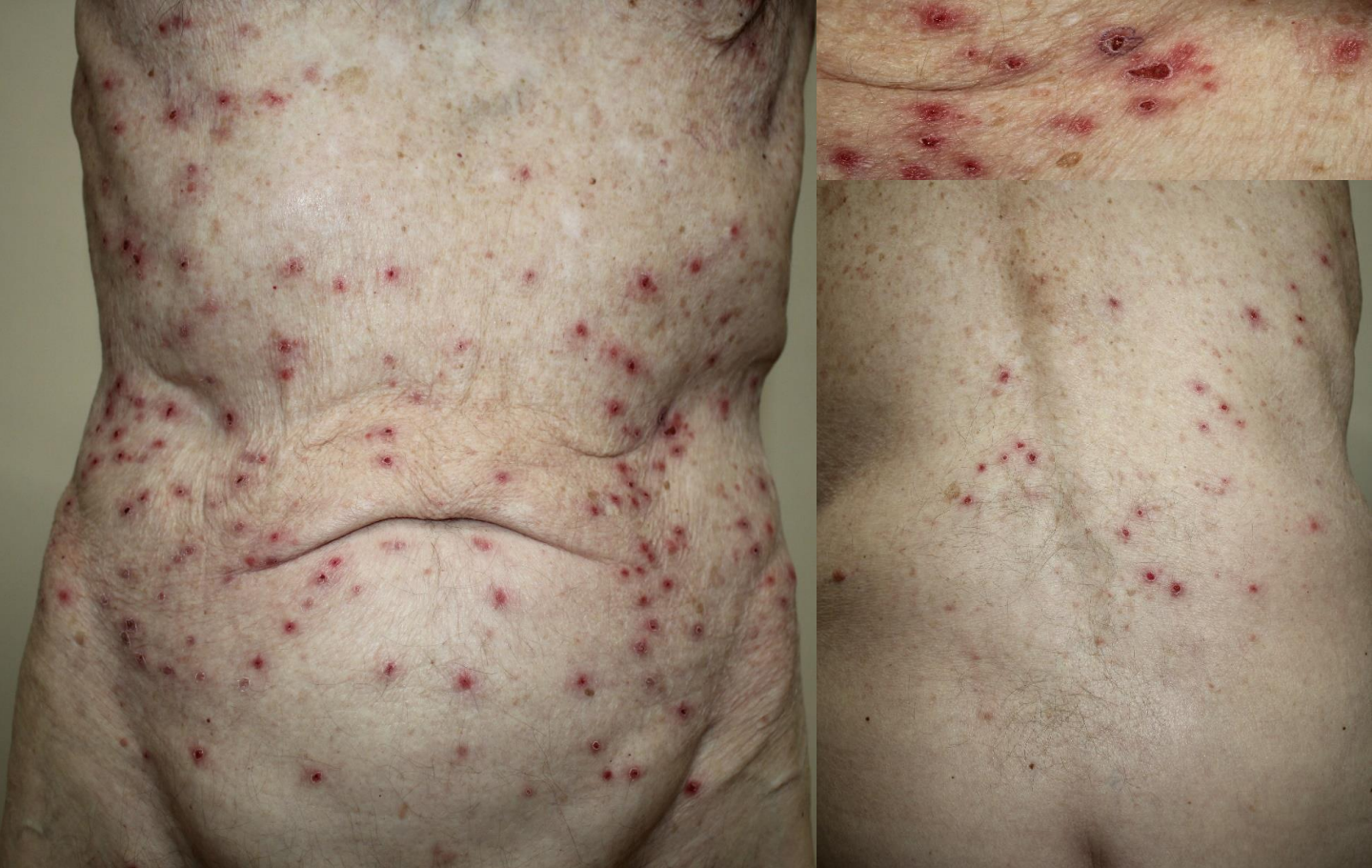V/S: BT 36.5 °C, BP 110/70 mmHg, P 80 bpm, RR 20 /min

HEENT: No pale conjunctivae, anicteric sclerae, no oral ulcer

CVS: }
RS: } Unremarkable
Abdomen: }

Lymph nodes: Non-palpable

Dermatological examination



Multiple discrete excoriated erythematous macules and papules with central scale crusts on abdomen and back

Problem list

1. Pruritic erythematous crusted papules on trunk for 2 weeks
2. Underlying diseases:
 - HTN, DLP, BPH
 - Hx of SCC parotid gland & base of tongue
 - Hx of multiple NMSC

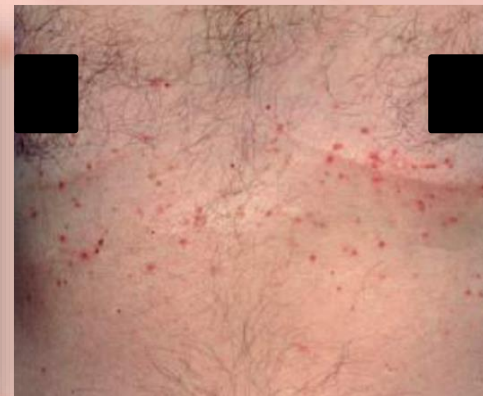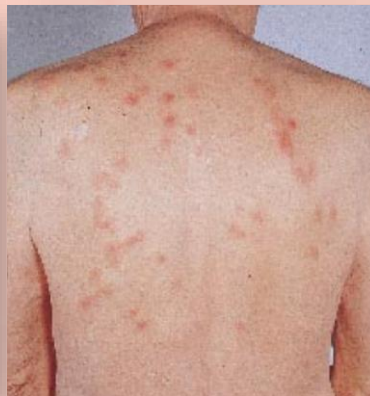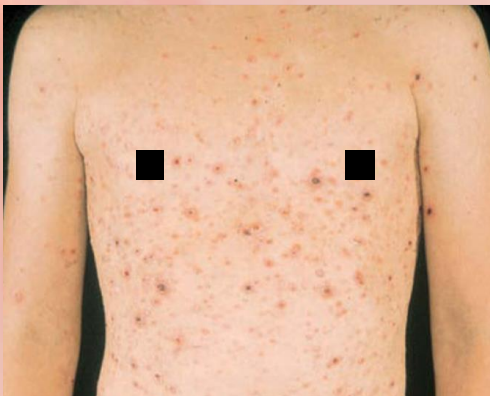Differential diagnosis

Inflammation

Pityriasis lichenoides
et varioliformis acuta
(PLEVA)

Exaggerated arthropod
bite reaction

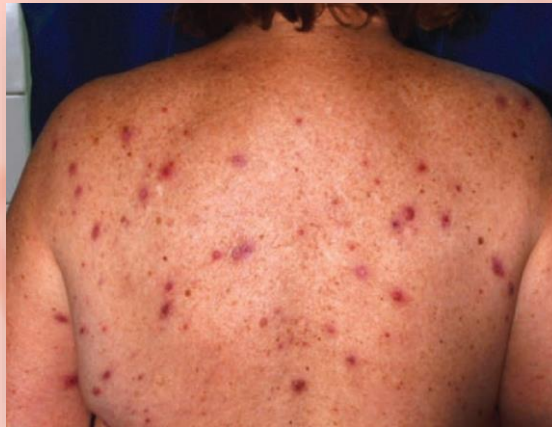Grover disease



Differential diagnosis

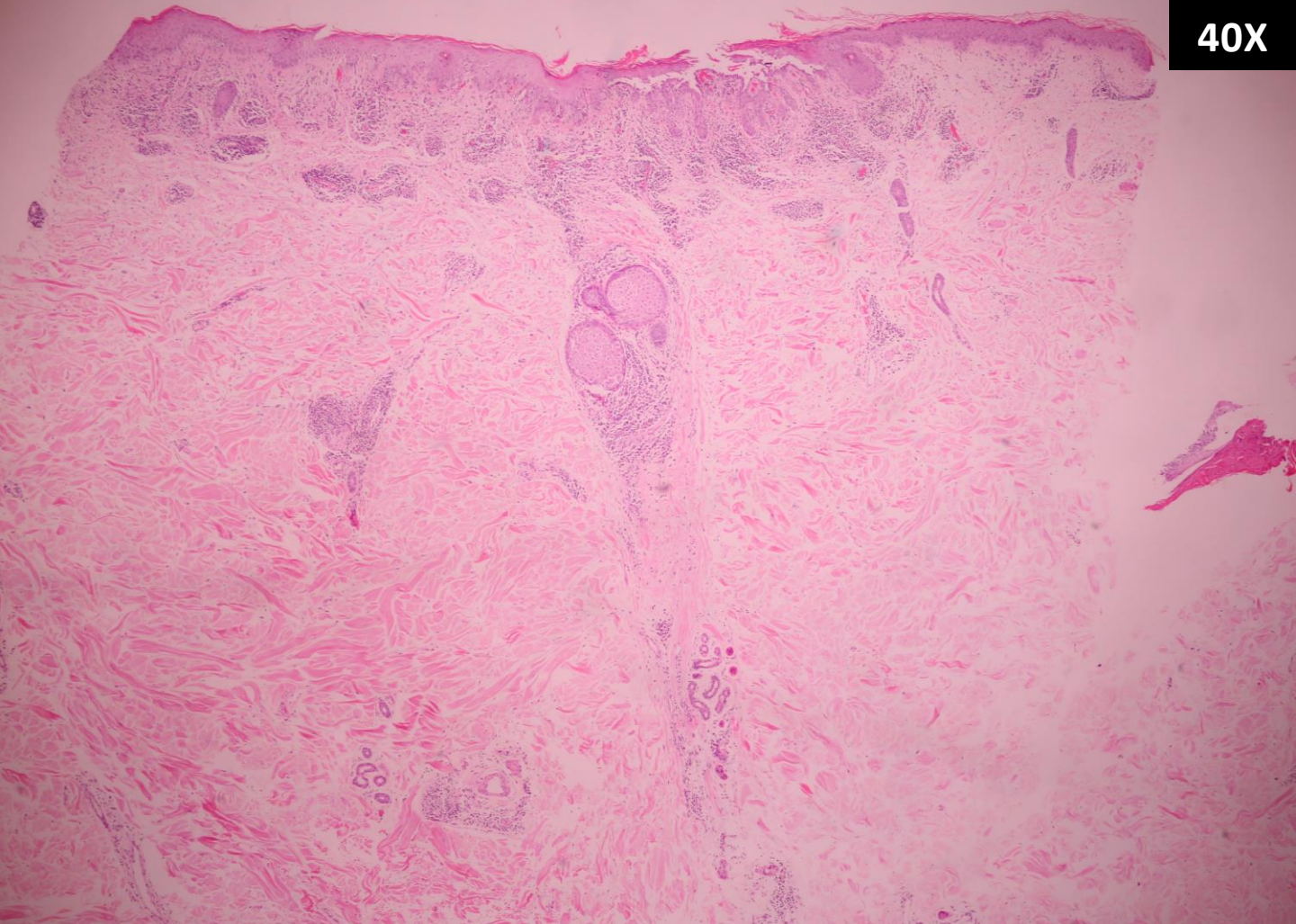
Tumor

Lymphomatoid papulosis

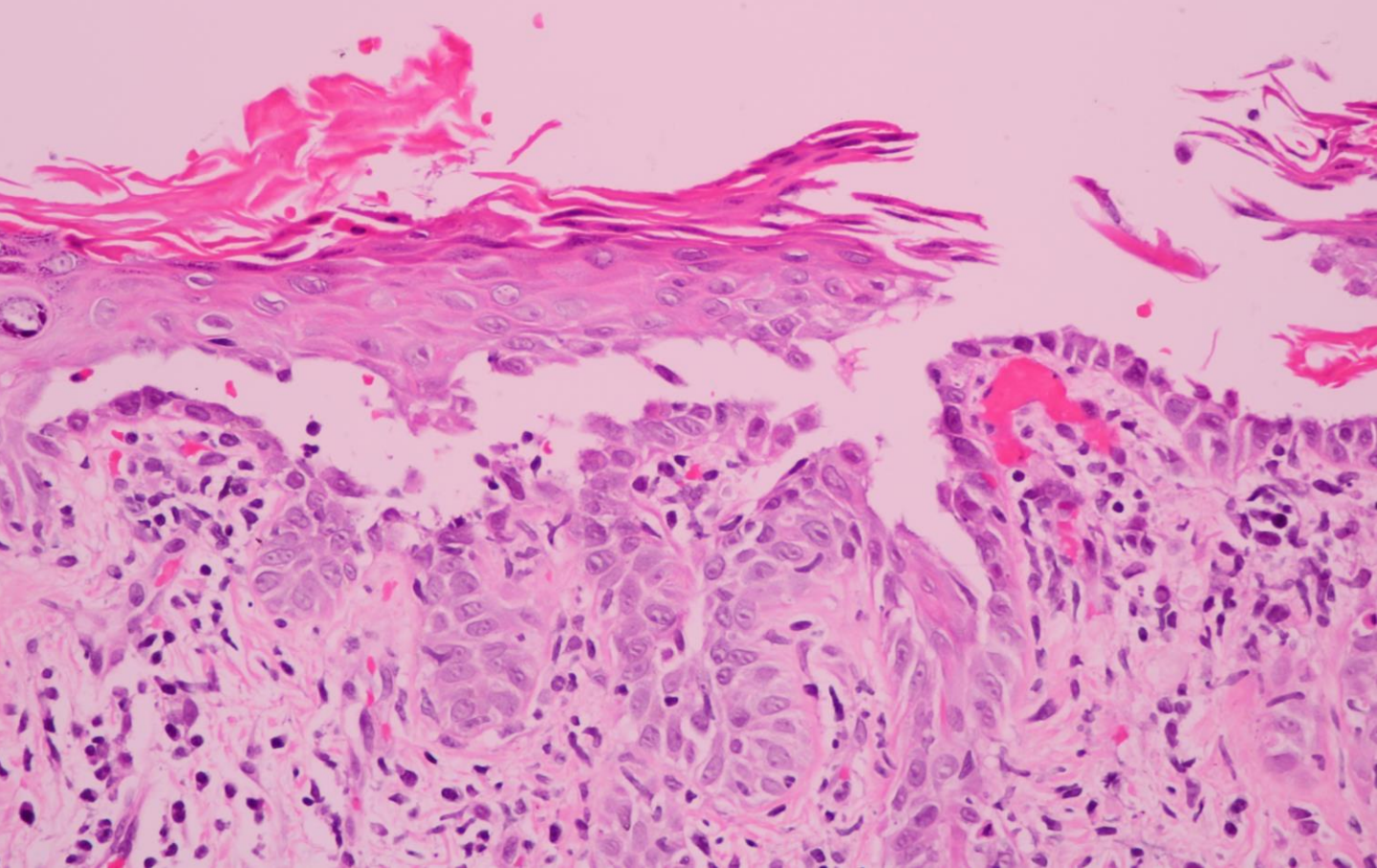


Histopathology

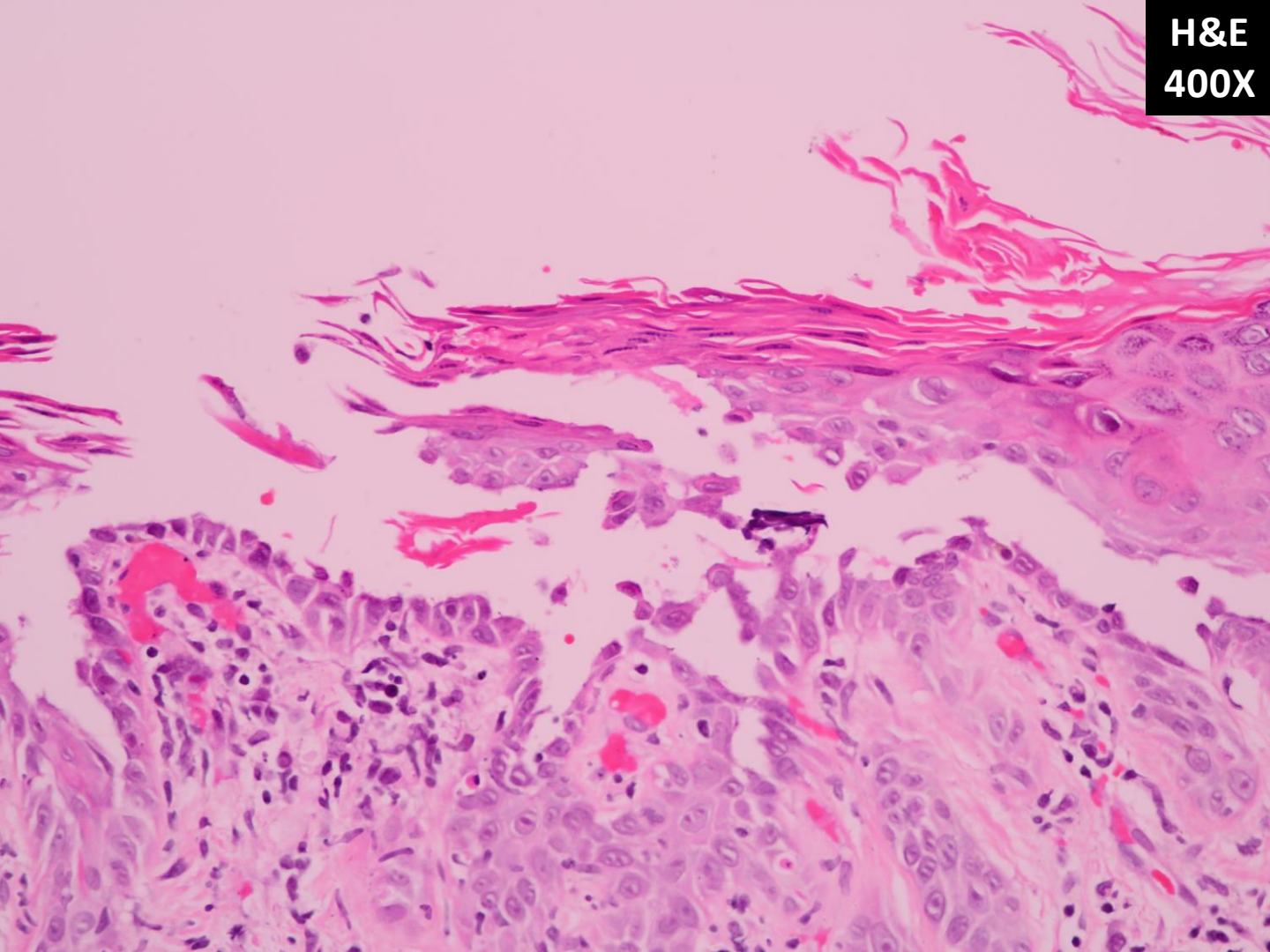
H&E
40X



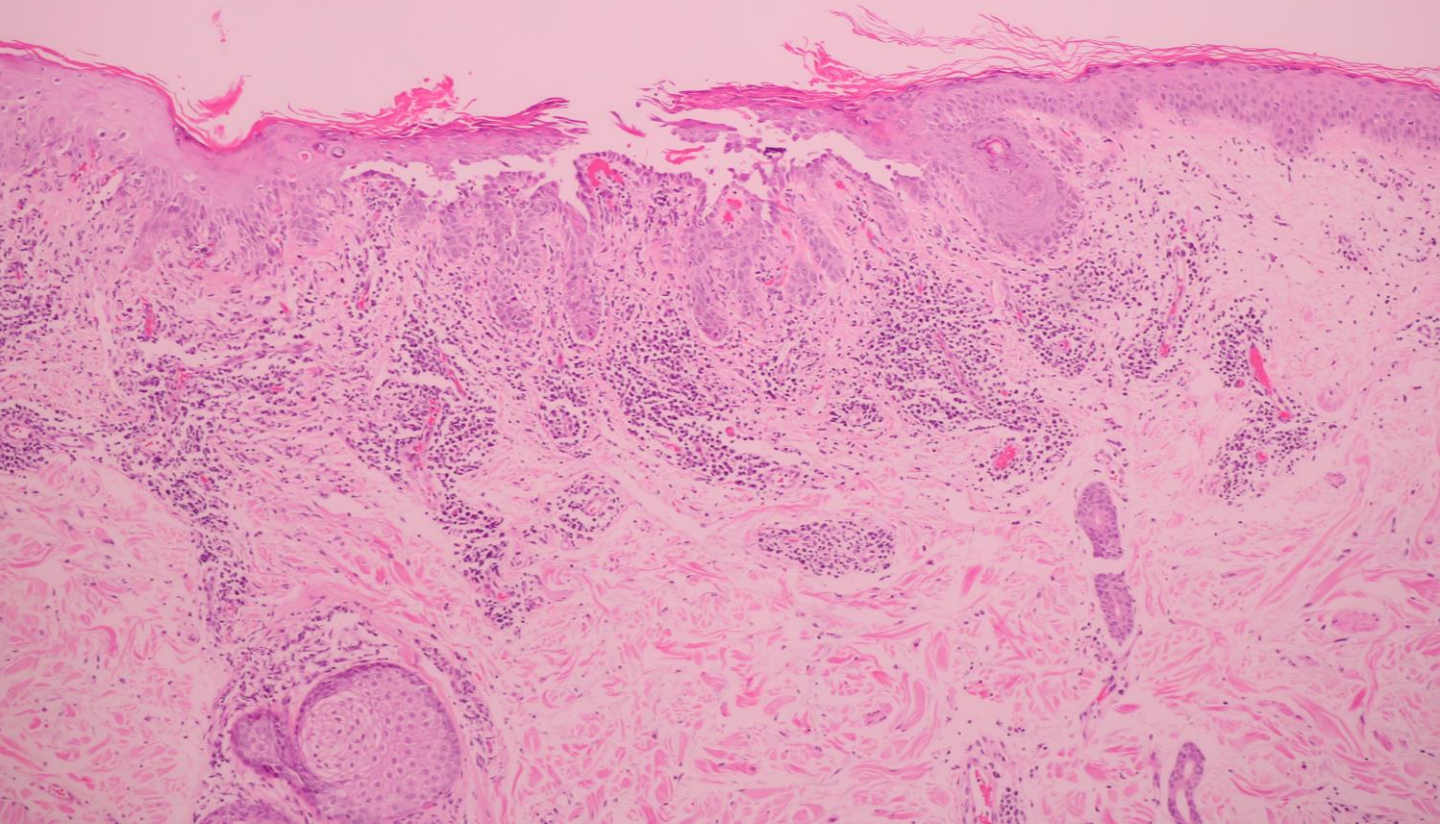
H&E
400X



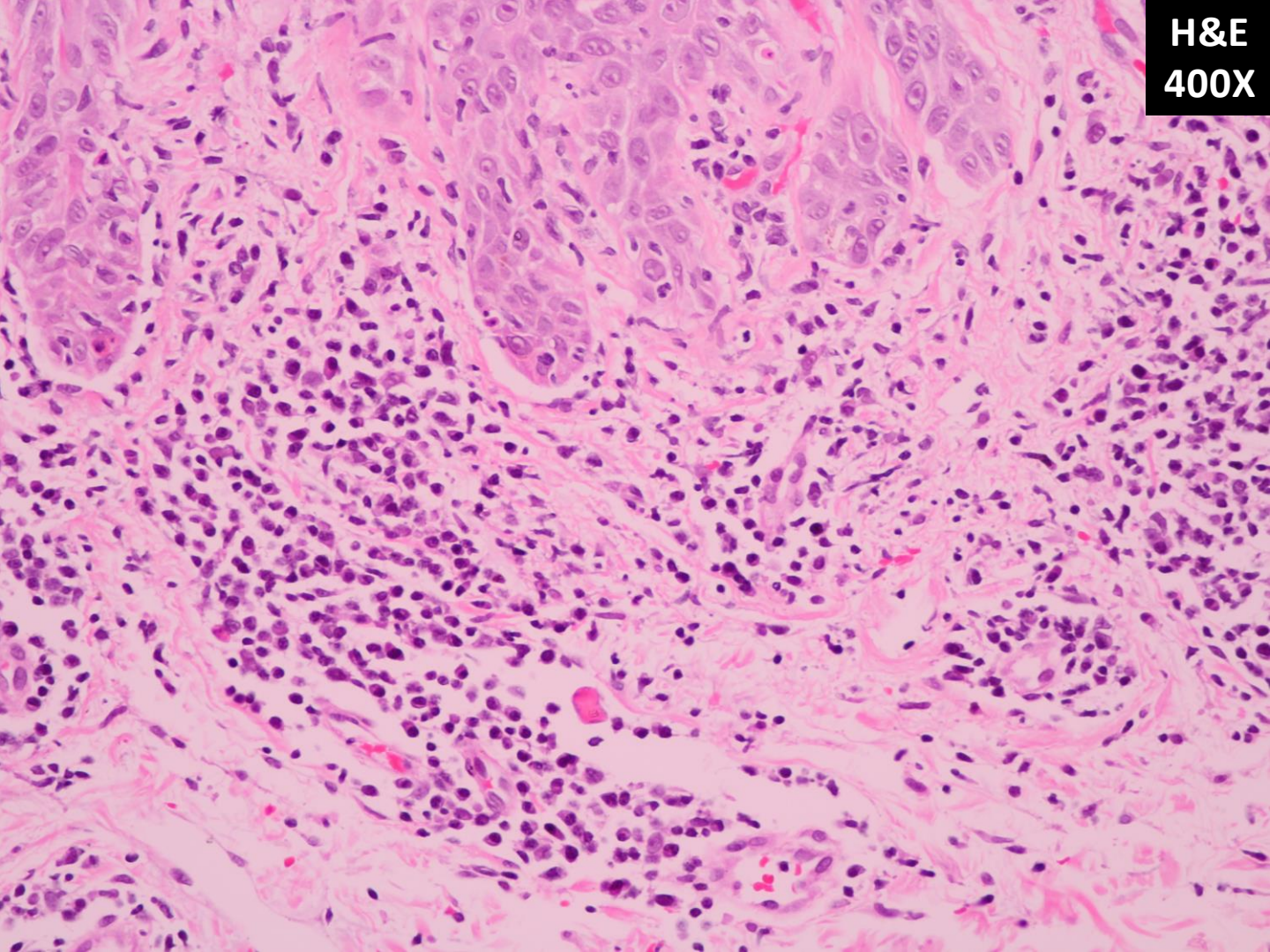
H&E
400X



H&E
100X



H&E
400X



Grover disease

Grover disease

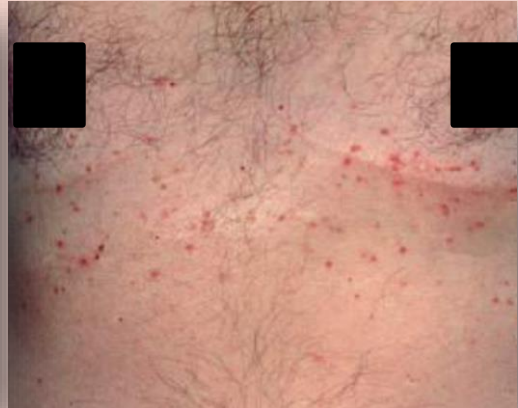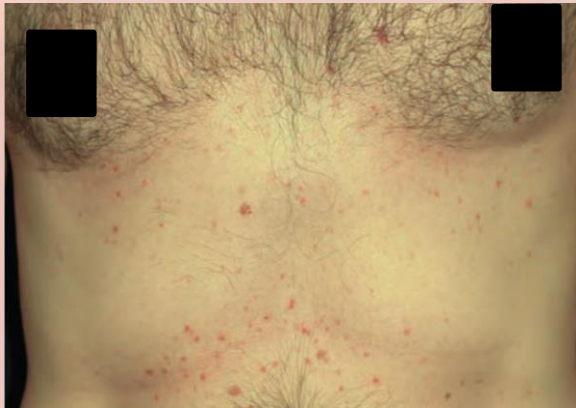- First described by Ralph Grover in 1970
- Nonfamilial condition
- Common in Caucasian
- Male: female = 3: 1
- Mean age = 61-year-old

Aggravating factors

- **Heat**, sweating
- Natural UV radiation
- Febrile illness
- Hospitalization, immobilization, bedridden status
- Drugs: interleukin 4 and D-penicillamine
- Seasonal: winter and summer

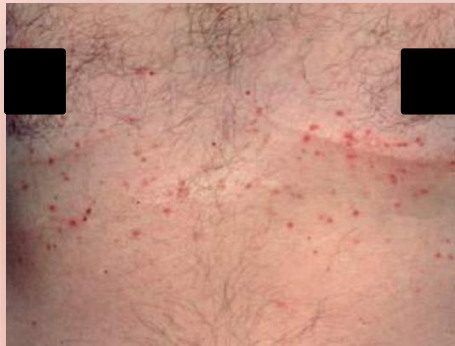Clinical features

Sudden onset of intense itchy erythematous papules and fragile vesicles with crusts on trunk



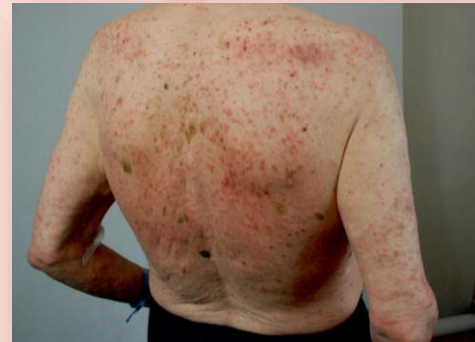Clinical features

Typical presentation



- Severe pruritus
- Papules & vesicles with crusts
- Distribution on trunk

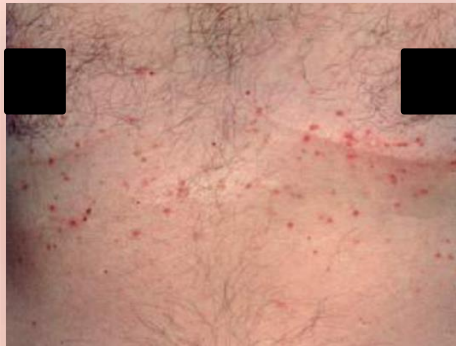Atypical presentation



- Asymptomatic
- Papules, vesicles & bullae
- Extensive distribution on trunk, extremities, head & neck

Associated conditions

Typical presentation



Inflammatory dermatoses

- Psoriasis
- Xerosis
- Dermatitis (ACD/ICD/AD)

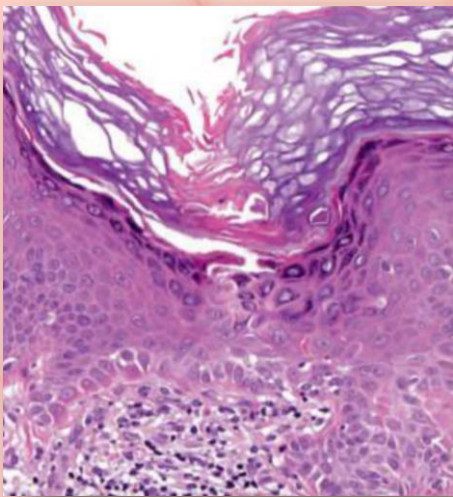
Atypical presentation



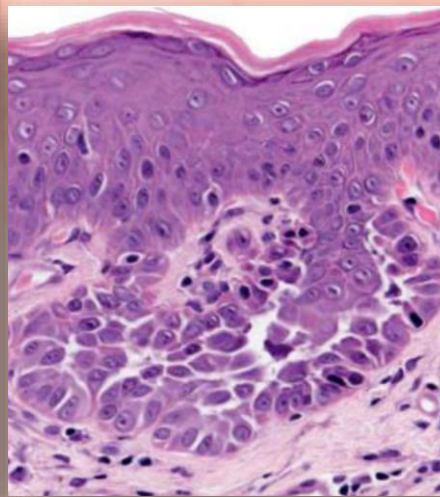
Malignancy & other

- Hematologic malignancy
- Nonhematologic malignancy
- Post-transplant

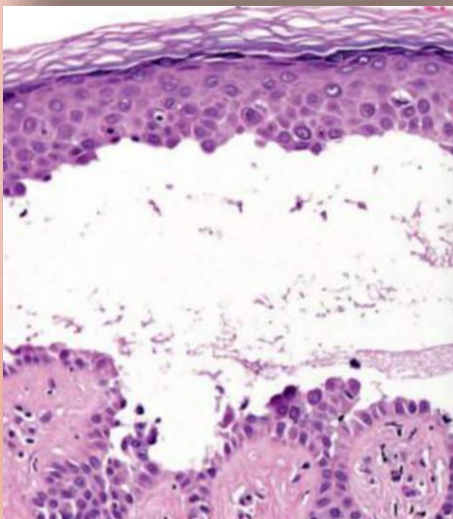
Darier disease-like



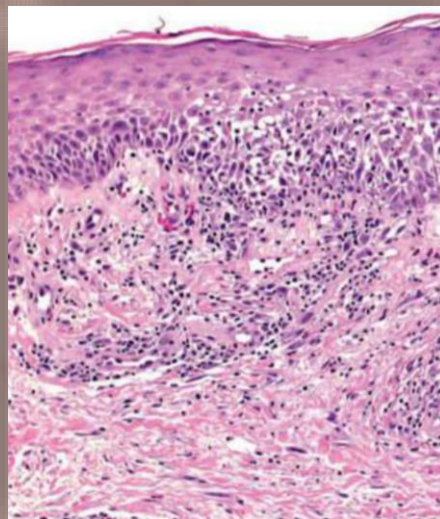
Hailey-Hailey disease-like



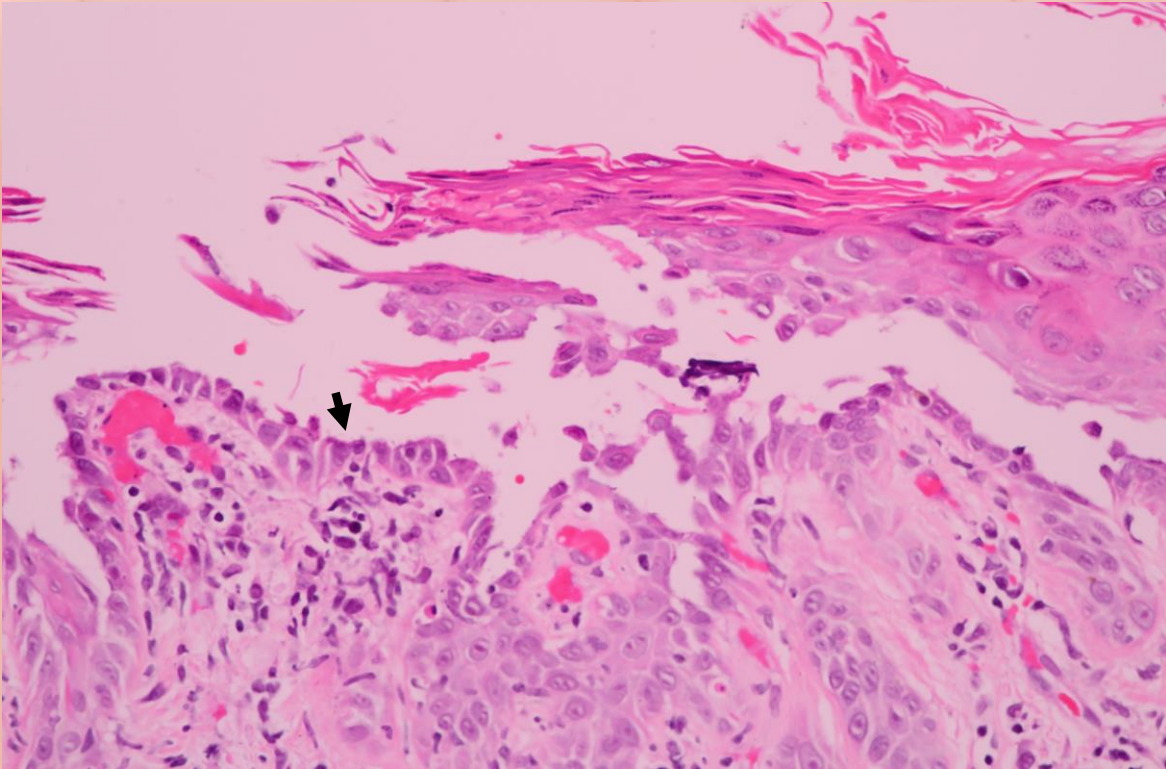
Pemphigus vulgaris-like



Spongiotic dermatitis



Histopathology



Treatment

Emollient & avoid precipitating factors

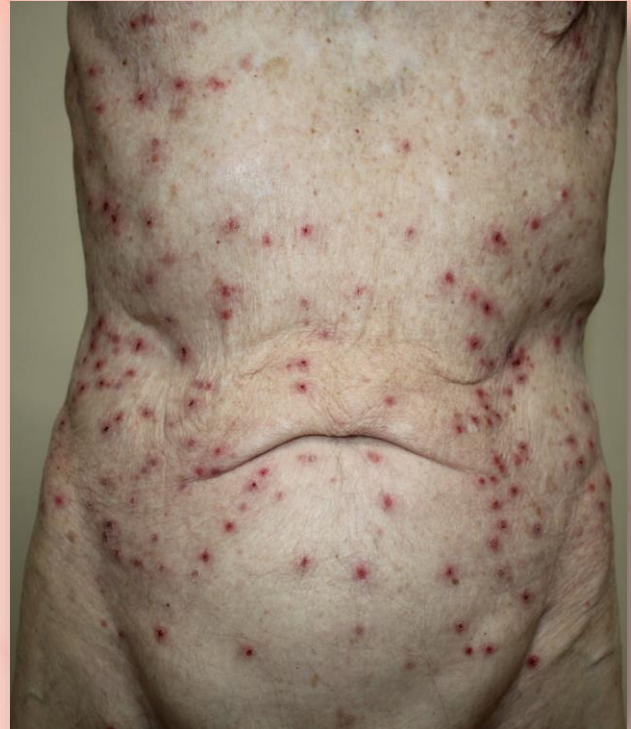- Mild
 - Topical corticosteroids, vitamin D analogues and calcineurin inhibitors
 - Systemic antihistamines
- Severe
 - Systemic corticosteroids, retinoids and methotrexate
 - Phototherapy
 - Etanercept

In this patient

- 0.1% triamcinolone acetonide milk lotion
apply on papular lesion BID
- Fusidic acid and betamethasone valerate cream
apply on ulceration BID
- Levocetirizine 10 mg/d PO
- Emollient
- Trigger avoidance

Case summary

- A 79 YO Caucasian male with multiple pruritic erythematous papules with crusts on trunk for 2 weeks
- **Dx:** Grover disease
- **Mx:** - Topical corticosteroids
- Systemic antihistamines
- Emollient
- Trigger avoidance



Take home messages

Grover disease

Pruritic erythematous papules with crusts on trunk in **Caucasians**

Many aggravating factors: **heat**

Atypical presentation associated with **underlying malignancy**

Histopathology (4 patterns) for the definitive diagnosis