



Interhospital Conference

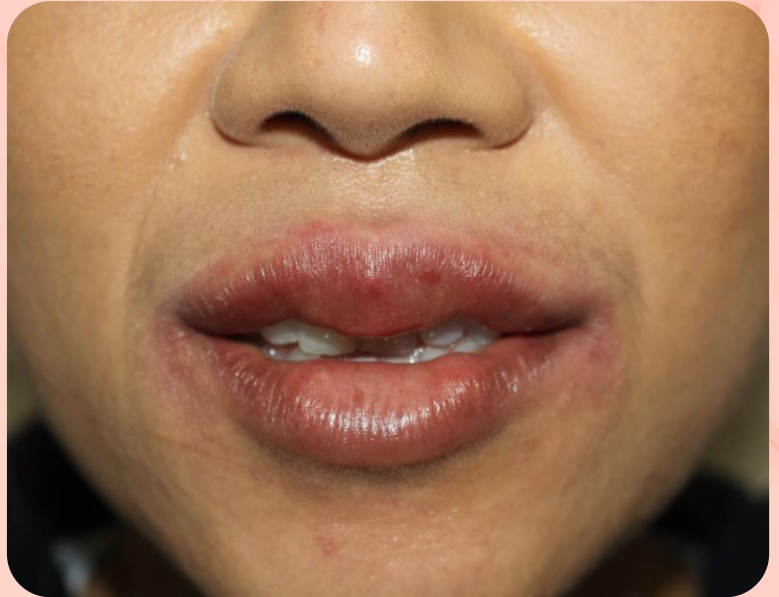Case 10

Natthachat Jurairattanaporn, MD, MSc
Vasanop Vachiramom, MD



A 40-year-old female

Multiple non-tender
nodules on both
upper and lower lips
for 3 months



Present illness

8/9/2019

**Filler injection
Upper &
lower lips**

HA* filler
No premixed
lidocaine
2.0 ml

27/11/2019

**Developed
lip swelling
& nodule
formation**

1st hyaluronidase
Clindamycin IV

29/11/2019

**No
improvement**

2nd hyaluronidase
Dexamethasone IV
Gentamicin IV

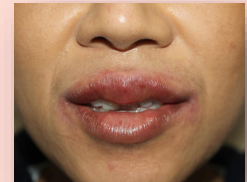5/12/2019

**Decrease
swelling
Persistent
nodules**

3rd hyaluronidase
Ceftriaxone IV

9/12/2019

**Visit
Ramathibodi
Hospital**



Ciprofloxacin PO
Amox-Clav PO
14 days

Past history

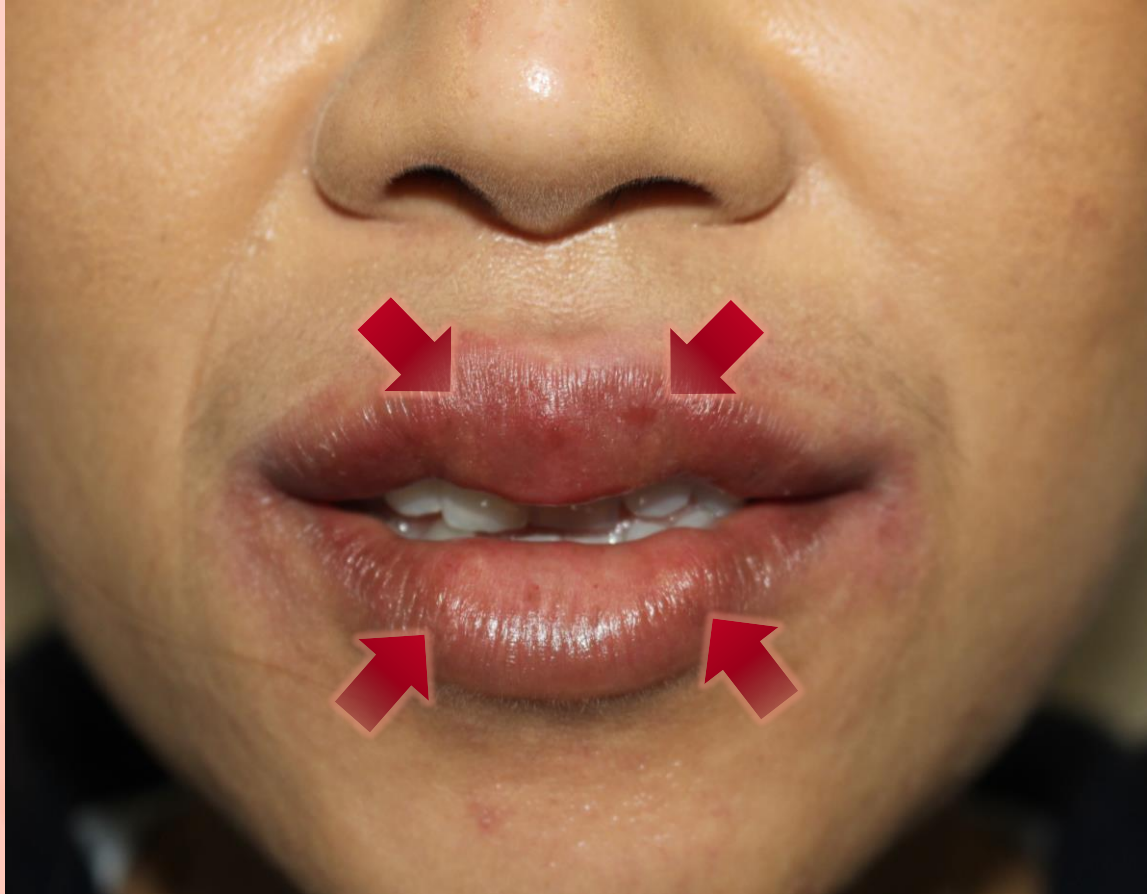
- No underlying conditions
- Denied history of filler injection
- H/O multiple botulinum toxin injections

Physical examination

- **Vital signs:** BT 36°C, BP 121/87 mmHg,
PR 87/min, RR 16/min
 - **HEENT:** no pale conjunctiva, anicteric sclera
 - **Lymph nodes:** impalpable
 - **CVS:**
 - **Lungs:**
 - **Abdomen:**
- } WNL

The background of the slide is a microscopic image of skin tissue, showing various cellular structures and fibers in shades of pink and orange. The tissue appears to be a cross-section of the epidermis and dermis, with some darker spots and fibers visible.

Dermatological examination



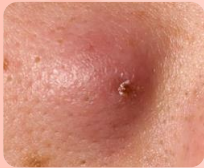**Four discrete non-tender firm nodules
on upper and lower lips with no fluctuation**

Problem list

**Late-onset non-inflammatory nodules
after HA filler injection for 3 months**

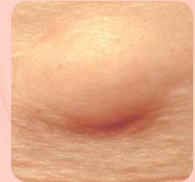Differential diagnosis

Late-onset (> 2 week)
nodule after filler injection



**Clinically
inflamed**

1. Biofilm
2. Atypical infection
3. Foreign body granuloma
4. Delayed-type hypersensitivity



**Clinically
non-inflamed**

1. Biofilm
2. Atypical infection
3. Foreign body granuloma
4. Delayed-type hypersensitivity
5. Filler migration

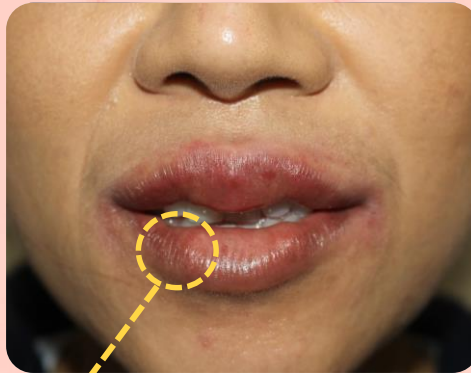1+2+3+4 รวมเรียกว่า Delayed Inflammatory Response Syndrome (DIRS)

Investigation

▪ Complete blood count

- Hb 13.8 g/dL
- Hct 38.1 %
- Platelet 203,000/mm³
- WBC 4,840/mm³ (N51, L34, M4, E10, B1)

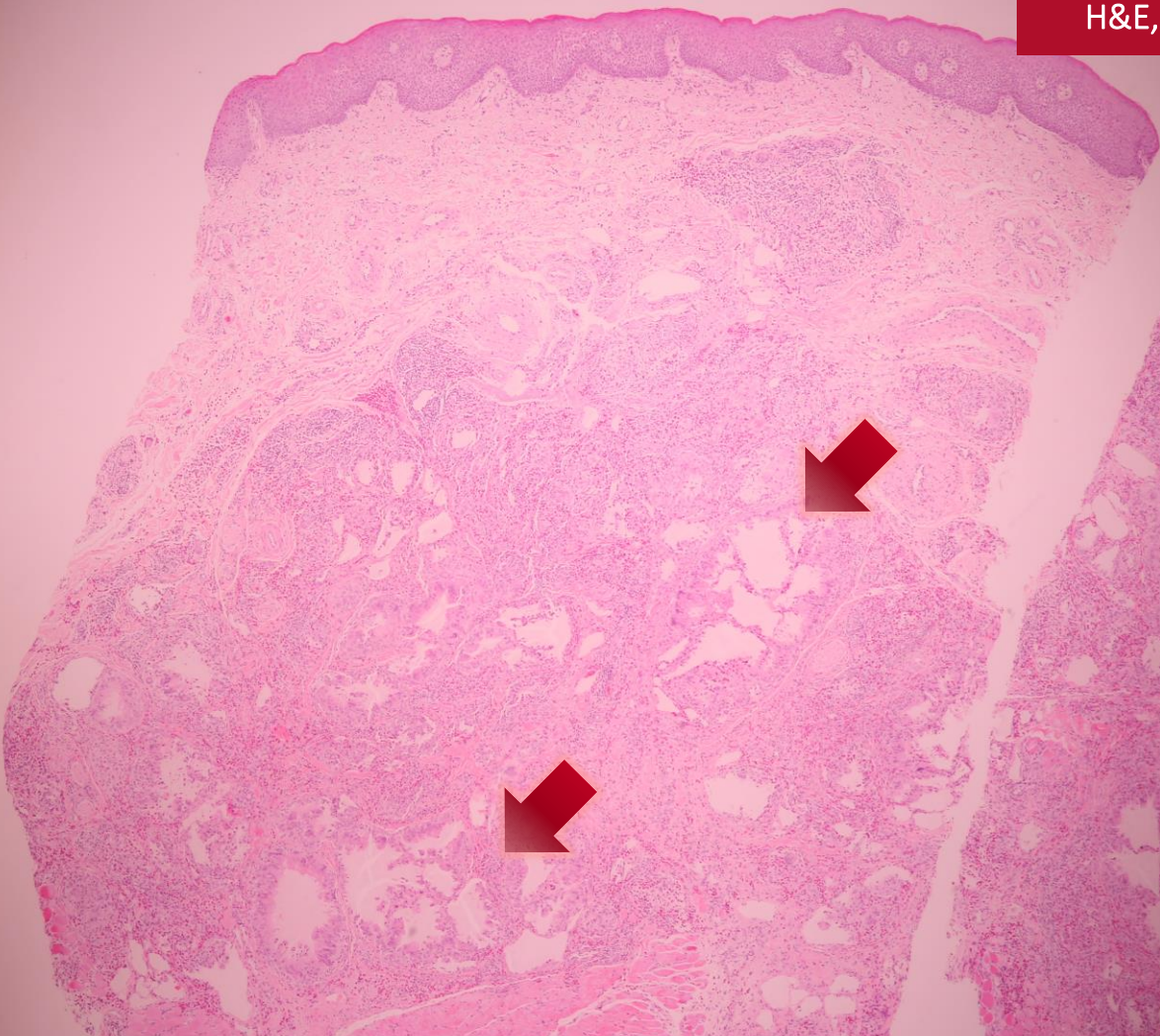
Investigation

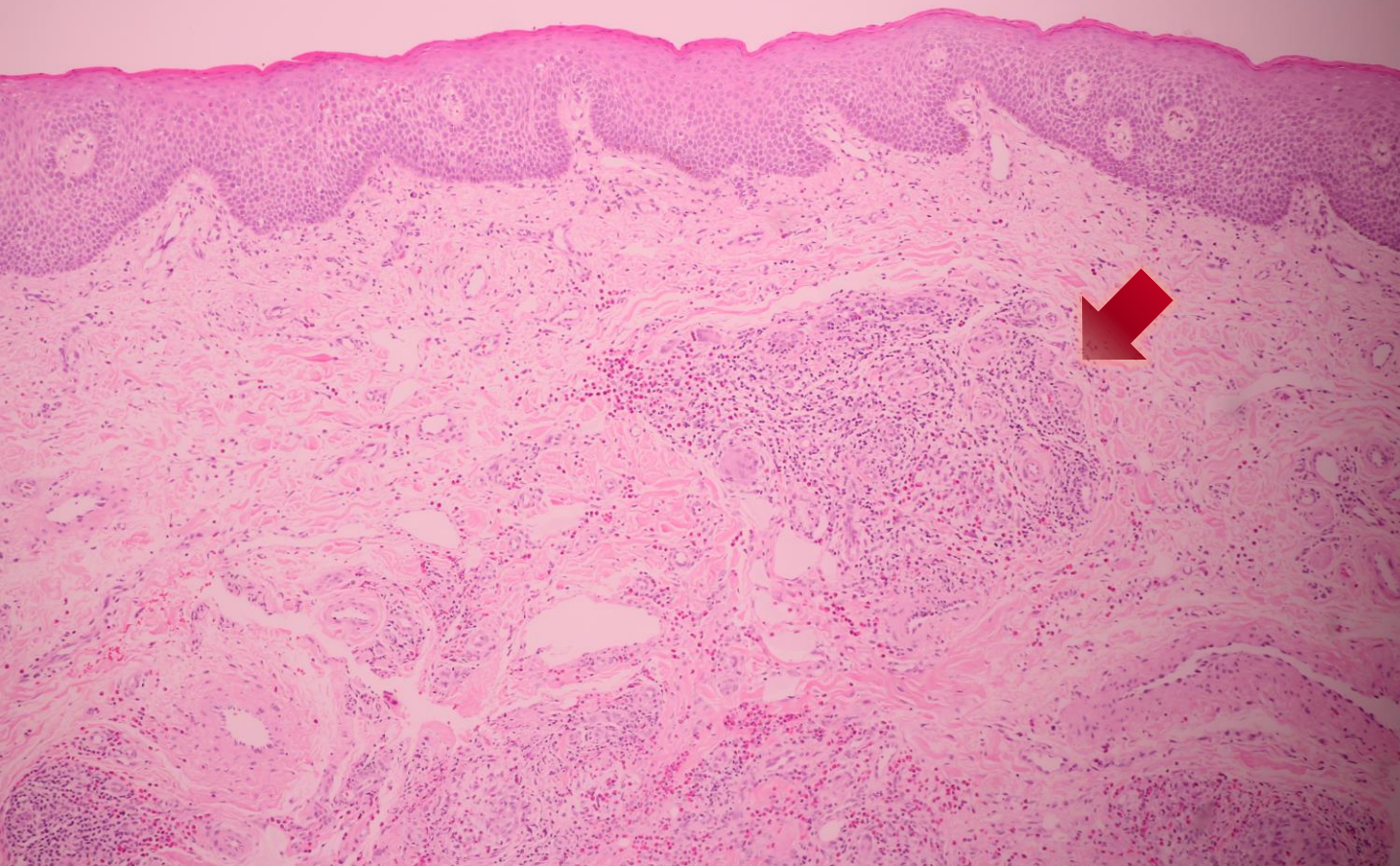


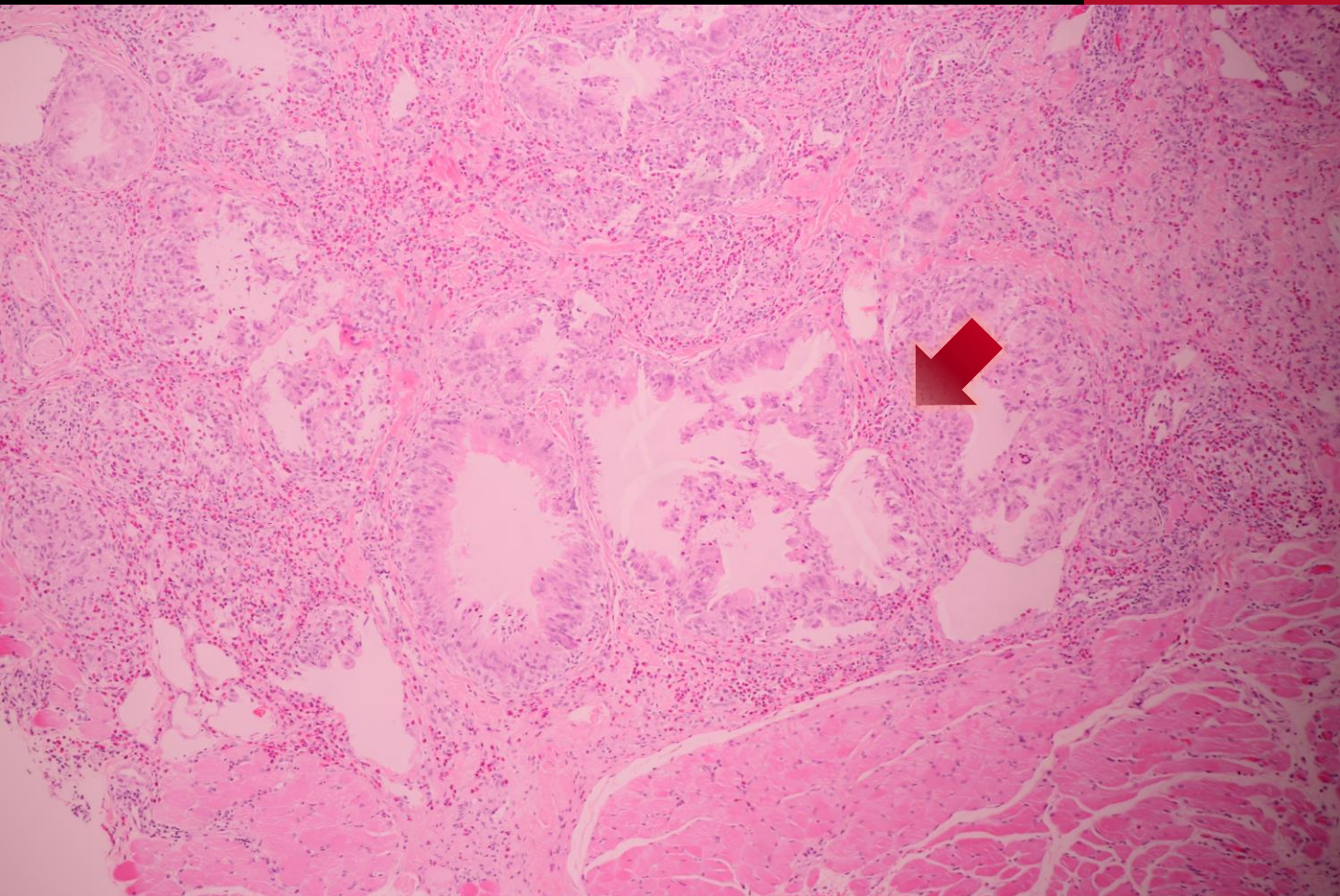
- **Incisional biopsy from lower lip**
 - Histopathology
 - Microbiological study

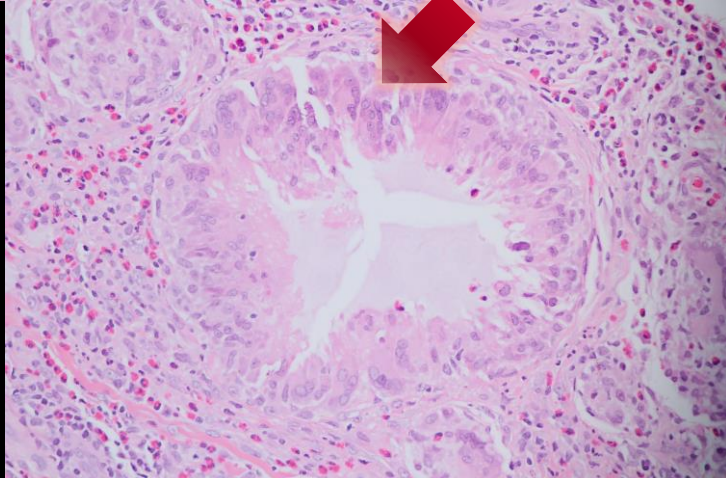
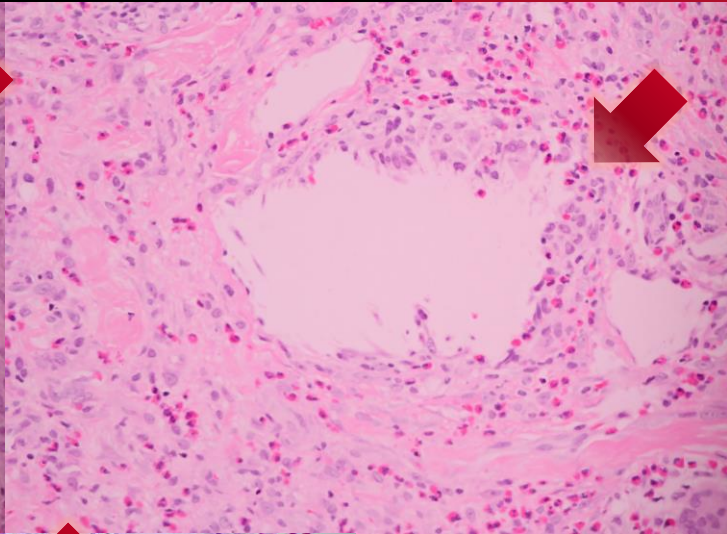
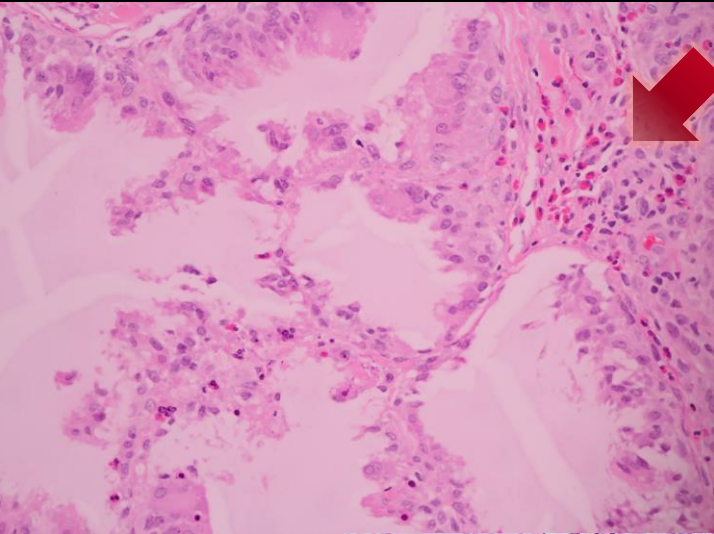


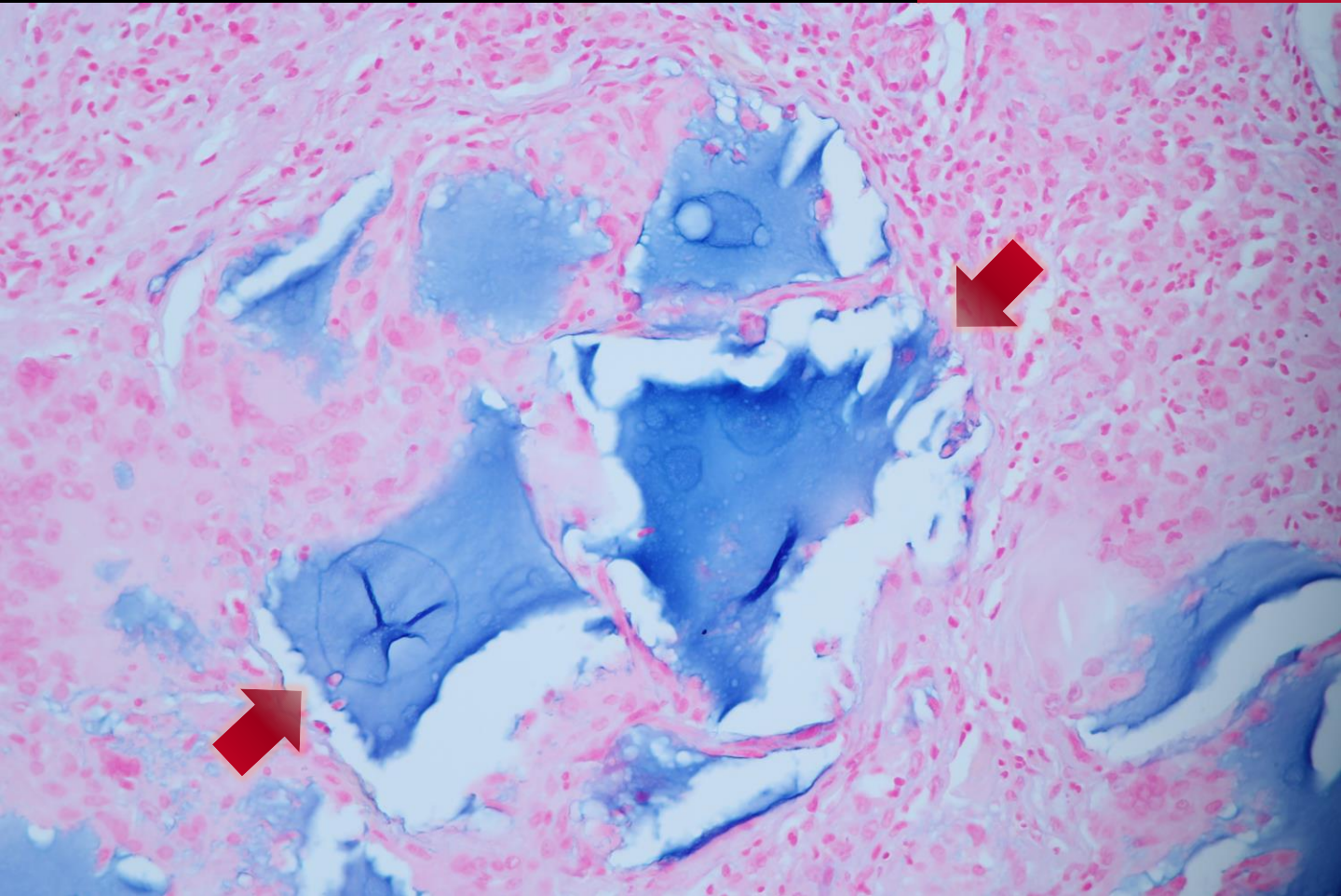
Histopathology











Investigation

Special stains	Result
PAS	No organism
GMS	
B&B	
AFB	
Fite	

Investigation

Tissue culture

Aerobe

Fungus

AFB

No growth

Tissue PCR

TB direct detection

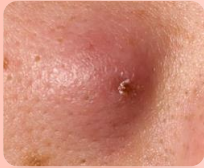16s

18s

Undetectable

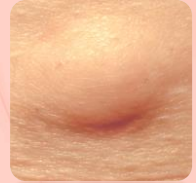Differential diagnosis

Late-onset (> 2 week)
nodule after filler injection



Clinically
inflamed

Clinically
non-inflamed



- Biofilm
- Atypical infection
- Foreign body granuloma

DIRS

Delayed Inflammatory Response Syndrome
Delayed type hypersensitivity

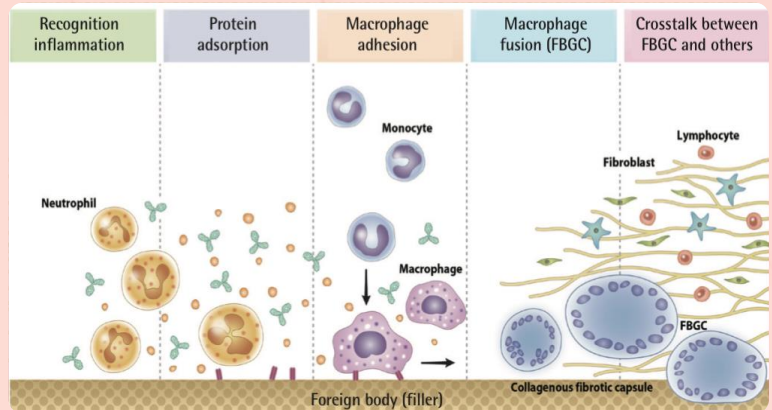
- Biofilm
- Atypical infection
- Foreign body granuloma
- Delayed type hypersensitivity
- Filler migration

The background of the slide is a light pinkish-orange color with a marbled, wavy pattern, resembling a histological section of tissue. A black rounded rectangular box is centered horizontally, containing the text "Filler granuloma" in white. The text is in a bold, sans-serif font.

Filler granuloma

Filler granuloma: risk

- Injected substance: silicone, paraffin
- Injected volume
- Repeated injections
- Impurities
- Particle size
- Particle smoothness
- Hydrophilicity





HA filler granuloma?

HA filler granuloma

- Incidence after HA filler injection **0.02-0.4%**

Retrospective review of delayed adverse events secondary to treatment with a smooth, cohesive 20-mg/mL hyaluronic acid filler in 4500 patients

Shannon Humphrey, MD,¹ Derek H. Jones, MD,² Jean D. Carruthers, MD,³ Alastair Carruthers, MD,⁴ Katie Belzney, MD,⁵ Naissan Wesley, MD,⁶ Jeanette M. Black, MD,⁷ Sherri Vanderveen, BA,⁸ and Ardalan Minokadch, MD, PhD⁹
Vancouver, British Columbia, Canada and Los Angeles, California

J Am Acad Dermatol. 2020;83:86-95.

REVIEW ARTICLE

WILEY | JCD
Journal of Cutaneous Medicine and Surgery

Granulomatous reaction to hyaluronic acid filler material in oral and perioral region: A case report and review of literature

Carlos Eduardo P Alcántara DDS, MSc, PhD¹ | Mariana S Noronha DDS² |
Joanna F Cunha DDS, MSc² | Isadora L Flores DDS, MSc, PhD¹ |
Ricardo A Mesquita DDS, MSc, PhD²

J Cosmet Dermatol. 2018;17:578-83.

Granulomatous reaction to Belotero Balance: A case study

Jessica Gandy, Dina Bierman & Christopher Zachary

To cite this article: Jessica Gandy, Dina Bierman & Christopher Zachary (2017) Granulomatous reaction to Belotero Balance: A case study, *Journal of Cosmetic and Laser Therapy*, 19:5, 307-309, DOI: 10.1080/14764172.2017.1299188

To link to this article: <https://doi.org/10.1080/14764172.2017.1299188>

J Cosmet Laser Ther. 2017;19:307-9.

ORIGINAL ARTICLE

Delayed immune-mediated adverse effects related to hyaluronic acid and acrylic hydrogel dermal fillers: clinical findings, long-term follow-up and review of the literature

J Alljotas-Reig,††* V Garcia-Gimenez‡¶

† Ageing Research and Autoimmune Diseases Unit, Department of Internal Medicine I, Hospital Universitari Vall d'Hebron, Barcelona, Spain

‡ Department of Medicine, Universitat Autònoma, Barcelona, Spain

§ Europa Medical Centre, Barcelona, Spain

¶ Sociedad Española de Medicina y Cirugía Cosmética, Barcelona, Spain

J Eur Acad Dermatol Venereol. 2008;22:150-61.

Delayed-type hypersensitivity

■ Clinical

- Swelling or nodule (usually with pruritus)
- May coexist with other causes of delayed nodule

■ Histopathology

- Little giant cells
- May mimics FB granuloma

■ Lab

- Anti-HA antibody


In our patient

FB granuloma



VS.

**Delayed-type
hypersensitivity**



**Late onset (> 2 week)
Nodule after filler injection**

**Clinically
inflamed**

**Clinically
non-inflamed**

DIRS*

**Filler
migration**

**Consider
Empirical antibiotics+
Hyaluronidase
Intralesional steroid**

Recovery

**No
improvement**

**Pretreatment
Intradermal skin test**

Work up

***Empirical antibiotics
Clarithromycin plus
moxifloxacin or ciprofloxacin
at least 2 weeks**

*DIRS: Delayed Inflammatory Response Syndrome

Skin biopsy
C/S (aerobic, anaerobic, AFB, fungus)
PCR/FISH of tissue sample

Positive C/S or PCR

Negative C/S or PCR

Biofilm

Atypical infection

FB granuloma

Delayed-type hypersensitivity

Consider
Antibiotics
Hyaluronidase

Consider
Hyaluronidase
Intralesional steroid

Recovery

No improvement

Pretreatment
Intradermal skin test

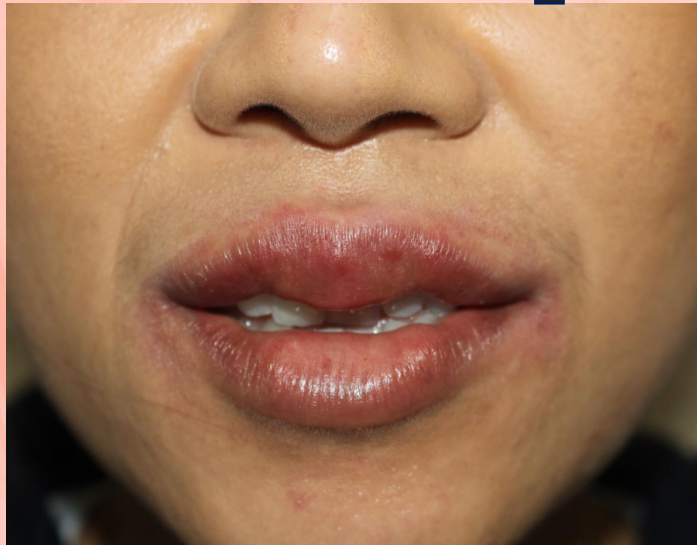Surgery
Intralesional 5-FU

Adapted from Aesthet Surg J. 2020;40:286-300.

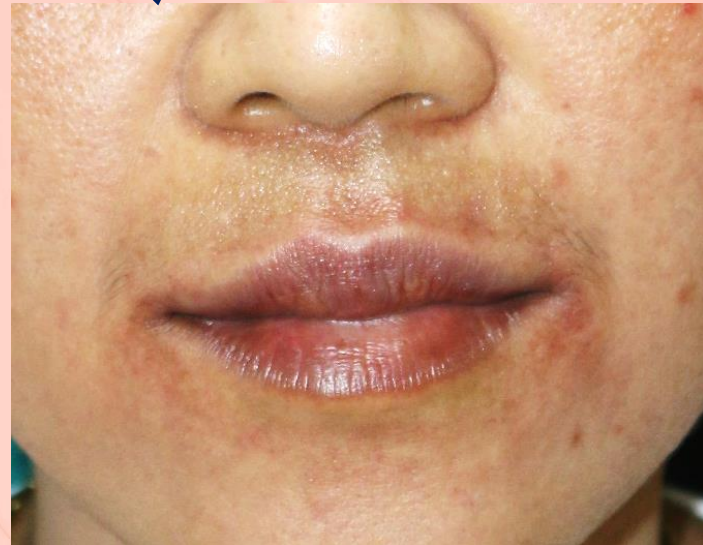Wilai Thanasarnakorn, Injectable filler complications and management, 2019

Treatment

1 week



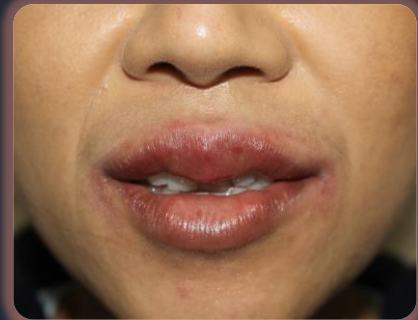Hyaluronidase injection
4th session – upper + lower lips 75 U



Hyaluronidase injection
5th session – lower lip 50 U

Case summary

- A 40-year-old female
- CC: multiple nodules on upper and lower lips after filler injection for 3 months
- **Dx: HA filler granuloma**
- Treatment: hyaluronidase injection



Take home message

- Late-onset nodules after filler injection
always rule out!!
 - Biofilm/atypical infection
 - Foreign body granuloma
 - Delayed-type hypersensitivity

****รายได้จากการจำหน่ายมอบให้มูลนิธิรามารินทร์ดีทั้งหมด โดยไม่หักค่าใช้จ่าย****

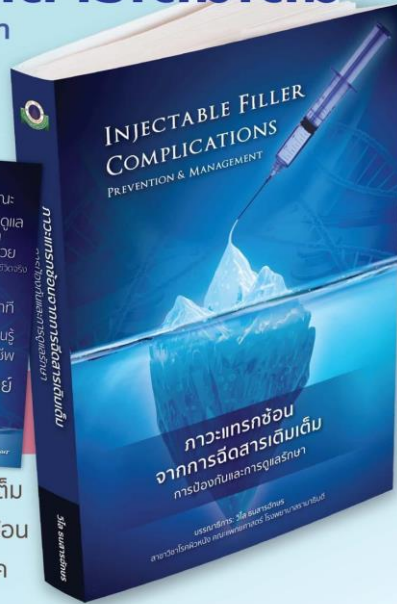
ภาวะแทรกซ้อน จากการฉีดสารเติมเต็ม

การป้องกันและการดูแลรักษา

พิมพ์ครั้งที่ 2
แถมฟรี ที่ค้นหนังสือ

ราคา
1,400.-
จาก 1,415.-
ส่งฟรี!!! ลงทะเบียน

โดย แพทย์หญิง
วิไล ธารสารอักษร
และคณะ



- ประวัติความเป็นมาของสารเติมเต็ม
- การป้องกันการเกิดภาวะแทรกซ้อน
- สารเติมเต็มชนิดกรดไฮยาลูโรนิก
- ไฮยาลูโรนيدات
- ภาวะแทรกซ้อนที่ไม่ได้เกิดจากเส้นเลือดตีตัน
- ภาวะแทรกซ้อนที่เกิดจากการติดเชื้อ
- ภาวะแทรกซ้อนเนื้อเยื่อขาดเลือด
- ภาวะแทรกซ้อนส่งผลต่อการมองเห็น
- กรณีผู้ป่วยศึกษา

วิธีการซื้อหนังสือ

- 1) โอนเงินเข้าบัญชีธนาคาร SCB 026-460-9696 (ผ่านทาง Mobile Application, ATM หรือ เคาน์เตอร์)
- 2) ส่งสลิปการโอนเงิน
e-mail: ramadermatology@gmail.com
พร้อมแจ้ง ชื่อ-นามสกุล ที่อยู่จัดส่ง เบอร์โทรศัพท์ (จัดส่งทาง Facebook ชื่อนุศจรูญสุทนต์)
- 3) รอเจ้าหน้าที่มอบเอกสารใน 2 วันทำการ